


OCTOBER 2017 VOL.2

MegaGen Articles

Study & Evidence on **MegaGen Products**



PUBLICATION
DIGITAL-IMPLANT-REGENERATION-SURFACE

POSTER
IMPORTANT NUMBERS IN IMPLANT DENTISTRY

MEGAGEN ARTICLES

Over the 15 years since MegaGen Co, Ltd. was established, we have been launched various implant systems, bone regeneration materials and digital technology solutions. Today MegaGen is a global company leading the trend of digital dentistry around the world. We export an ever increasing product range to over 90 countries in the rapidly changing Implant dentistry market. We attribute our outstanding growth not simply to the high quality products we manufacture but to the scientific technological advances and the practical concepts we present which are supported by our significant clinical resources and background and are evidenced in the numerous clinical, studies & scientific articles which have been accumulated over these years. I'd like to take this opportunity to thank you all, people who have played an integral part in this weighty contribution to our company development; and above all developing a resource for all clinicians & researchers.

In 2013, MegaGen gathered articles relating to our products and published a book of studies, "Study & Evidence on MegaGen Products". We continue to focus on gathering clinical evidence based on scientifically proven data. We have been working with esteemed collaborators around the world to put our proposed solutions scientifically and clinically to the test. We are confident that the evidence we present here will arouse your interest & we look forward to presenting continuing studies and updated information in our future publications.

MegaGen strongly believes that scientific, clinical evidence and information sharing are the keys to enable our customers to maintain the highest level of performance and to ensure the best possible outcomes for our patients. With this publication we have brought together opinion leaders from all over the world to help you achieve optimum clinical results.

Please contact us for any additional information or with any queries - both with regards to science or cases presented here or for details of our MegaGen systems. We would also love to hear from you if you wish to propose further studies.

We look forward to hearing from you!

DOCUMENTATION

DIGITAL

10 **01.** Presurgical Cone Beam Computed Tomography Bone Quality Evaluation for Predictable Immediate Implant Placement and Restoration in Esthetic Zone
Corina Marilena Cristache
Case Rep Dent, 2017; 2017: 1096365, Published online 2017 Feb 22, doi: 10.1155/2017/1096365

12 **02.** Implant Stability in the Posterior Maxilla: A Controlled Clinical Trial
Raquel Zita Gomes, Mario Ramalho de Vasconcelos, Isabel Maria Lopes Guerra, Rute Alexandra Borges de Almeida, and Antonio Cabral de Campos Felino
BioMed Research International Volume 2017 (2017), Article ID 6825213, 11 pages

14 **03.** Accuracy of a direct drill-guiding system with minimal tolerance of surgical instruments used for implant surgery: a prospective clinical study
Du-Hyeong Lee, Seo-Young An, Min-Ho Hong, Kyoung-Bae Jeon, Kyu-Bok Lee
J.Adv. Prosthodont, 2016 Jun; 8(3): 207-213, Published online 2016 Jun 17, doi: 10.4047/jap.2016.8.3.207

16 **04.** Virtual Planning of 3-Dimensional Implant Position Using a Radiopaque Scanning Tray
Jong-Eun Kim, June-Sung Shim
The Korean Academy of Oral & Maxillofacial Implantology Vol, 20, No, 4, 2016

18 **05.** Comparative Study on Clearance between Drilling and Bushing of Various Implant Guide Systems
Ji-Man Park, Seong-Joo Heo, Eun-Jin Park
Journal of the Korean Academy of Oral & Maxillofacial Implantology, 2014 ; 18 (3) : p.194-202

IMPLANT

20 **06.** Immediate Loading of Single Implants in the Anterior Maxilla: A 1-Year Prospective Clinical Study on 34 Patients
Miguel Stanley, Filipa Calheiros Braga, and Beatriz Mota Jordao
Hindawi International Journal of Dentistry Volume 2017, Article ID 8346496, 11 pages

22 **07.** Accuracy Evaluation of a Stereolithographic Surgical Template for Dental Implant Insertion Using 3D Superimposition Protocol
Corina Marilena Cristache, Silviu Gurbanescu
Int J Dent, 2017; 2017: 4292081, Published online 2017 May 7, doi: 10.1155/2017/4292081

24 **08.** Dental implants with internal versus external connections: 5-year post-loading results from a pragmatic multicenter randomised controlled trial
Marco Esposito, Hassan Maghaireh, Roberto Pistilli, Maria Gabriella Grusovin, Sang Taek Lee, Anna Trullenque-Eriksson, Federico Gualini
Eur J Oral Implantol, 2016;9 Suppl 1(2):129-41.

26 **09.** Short (6-mm) dental implants versus sinus floor elevation and placement of longer (≥ 10 -mm) dental implants: a randomized controlled trial with a 3-year follow-up.
Bechara S, Kubilius R, Veronesi G, Pires JT, Shibli JA, Mangano FG.
Clin Oral Implants Res, 2016 Jul 12, doi: 10.1111/clr.12923

28 **10.** The effect of implant macro-thread design on implant stability in the early post-operative period: a randomized, controlled pilot study
Jeffrey J. McCullough, Perry R. Klokkevold
Clin Oral Implants Res, 2016 Oct 3, doi: 10.1111/clr.12945.

30 **11.** Immediate Loading of Single Implants: A 2-Year Prospective Multicenter Study
Mangano C, Raes F, Lenzi C, Eccellente T, Ortolani M, Luongo G, Mangano F.
Int J Periodontics Restorative Dent, 2017 Jan/Feb;37(1):69-78, doi: 10.11607/prd.2986.

32 **12.** Immediate, early (6 weeks) and delayed loading (3 months) of single implants : 4-month post-loading from a multicenter pragmatic randomised controlled trial.
Esposito M, Siormpas K, Mitsias M, Bechara S, Trullenque-Eriksson A, Pistilli R.
Eur J Oral Implantol, 2016;9(3):249-260

34 **13.** Immediate Loading of Tapered Implants Placed in Postextraction Sockets and Healed Sites.
Han CH, Mangano F, Mortellaro C, Park KB
J Craniofac Surg, 2016 Jul;27(5):1220-7.

36 **14.** Fixed Full Arches Supported by Tapered Implants with Knife-Edge Thread Design and Nanostructured, Calcium-Incorporated Surface: A Short-Term Prospective Clinical Study
Soheil Bechara, Algirdas Lukosiunas, Giorgio Andrea Dolcini, Ricardas Kubilius
BioMed Research International Volume 2017 (2017), Article ID 4170537, 11 pages

38 **15.** Early bone formation around immediately loaded implants with nanostructured calcium-incorporated and machined surface: a randomized, controlled histologic and histomorphometric study in the human posterior maxilla
Francesco Guido Mangano & Giovanna Iezzi, Jamil Awad Shibli, Jefferson Trabach Pires, Giuseppe Luongo, Adriano Piattelli, Carlo Mangano
Clin Oral Investig, 2017 Feb 2, doi: 10.1007/s00784-017-2061-y. [Epub ahead of print]

40 **16.** Early Bone Formation around Immediately Loaded Transitional Implants Inserted in the Human Posterior Maxilla: The Effects of Fixture Design and Surface
CarloMangano, Jamil Awad Shibli, Jefferson Trabach Pires, Giuseppe Luongo, Adriano Piattelli, Giovanna Iezzi
Biomed Res Int, 2017;2017:4152506, doi: 10.1155/2017/4152506, Epub 2017 Feb 9.

42 **17.** Soft Tissue Stability around Single Implants Inserted to Replace Maxillary Lateral Incisors: A 3D Evaluation
F. G. Mangano, F. Luongo, G. Picciocchi, C. Mortellaro, K. B. Park, and C. Mangano
International Journal of Dentistry Volume 2016 (2016), Article ID 9393219, 9 pages

44 **18.** The effect of the thread depth on the mechanical properties of the dental implant
Sun-Young Lee, Sung-Jun Kim, Hyun-Wook An, Hyun-Seung Kim1, Dong-Guk Ha, Kyung-Ho Ryo, Kwang-Bum Park
J.Adv. Prosthodont 2015;7:115-21

46 **19.** The 10,6 μ m SuperPulse CO2 laser may alleviate the late implant failure linked to tissue tension
Jack T. Krauser, Peter Vitruk
Published: 2015 in Implant Practice US 8 (5), 30-35

48 **20.** Immediate implant placement in the esthetic zone utilizing the "root membrane" technique: clinical results up to 5 years post-loading.
Siormpas KD, Mitsias ME, Kontsiotou-Siormpa E, Garber D, Kotsakis GA.
Int J Oral Maxillofac Implants, 2014 Nov-Dec;29(6):1397-405

50 **21.** The management of immediate implant placement to optimize aesthetic outcome in the anterior maxilla
Howard Gluckman and Jonathan Du Toit
INTERNATIONAL DENTISTRY - AFRICAN EDITION VOL, 4, NO, 4: 48-57

52 **22.** New possibilities - avoiding bone grafting with short implants
Soheil Bechara, Kwang Bum Park, Ricardas Kubilius, Algirdas Lukosiunas
IDT June 2012 17:20

54 **23.** Effect of XPEED® on Ti implants with deep threads
Sun-Young Lee, Dong-Jun Yang, Shin-il Yeo, Hyun-Wook An, Sung-Jun Kim, Won-Mi Choi, Kwang-Bum Park
Key Engineering Materials Vols, 493-494 (2012) pp 442-446

DOCUMENTATION

IMPLANT

56

2011

24

The cytocompatibility and osseointegration of the Ti implants with XPEED surface

Sun-Young Lee, Dong-Jun Yang, Shin-il Yeo, Hyun-Wook An, Kyung-Ho Ryoo, Kwang-Bum Park

COIR-Feb-11-OR-2079,R2

58

2011

25

Recent Changes of Dental Implant Design - AnyRidge

Kwang Bum Park

Proceedings of the International Dental Materials Congress 2011, 2011.5, 39-45 (7 pages)

REGENERATION

60

2016

26

Alveolar Ridge Reconstruction with Titanium Meshes and Simultaneous Implant Placement: A Retrospective, Multicenter Clinical Study

Raquel Zita Gomes, Andres Paraud Freixas, Chang-Hun Han, Sohueil Bechara, and Isaac Tawil

BioMed Research International Volume 2016 (2016), Article ID 5126838, 12 pages

62

2014

27

Ridge regeneration With a titanium membrane

Dinesh Vegad BDS

Premium Practice Dentistry

64

2011

28

In Vitro and In Vivo Osteoinductive and Osteoconductive Properties of a Synthetic Bone Substitute

Enrico Conserva, Federico Foschi, Ranieri Cancedda, Maddalena Mastrogiacomo

Oral and Craniofacial Tissue Engineering 2011;1:244-251

66

2010

29

Synchrotron X-Ray Bioimaging of Bone Regeneration by Artificial Bone Substitute of MegaGen Synthetic Bone and Hyaluronate Hydrogels.

Junseok Yeom , Soeun Chang, Jung Kyu Park, Jung Ho Je, Dong Jun Yang, Seok kyu Choi, Hong-In Shin, Seung-Jae Lee, Jin-Hyung Shim, Dong-Woo Cho, Sei Kwang Hahn

Tissue Eng Part C Methods, 2010 Oct;16(5):1059-68, doi: 10.1089/ten.TEC.2009.0759.

68

2012

30

Safety and effectiveness of maxillary early loaded titanium implants with a novel nanostructured calcium-incorporated surface (Xpeed): 1-year results from a pilot multicenter randomized controlled trial

Marco Esposito, Maria Gabriella Grusovin, Gerardo Pellegrino, Elisa Soardi, Pietro Felice

Eur. J. Oral Implantol, 2012;5(3)

SURFACE

70

2007

31

Effects of calcium ion incorporation on bone healing of Ti6Al4V alloy implants in rabbit tibiae

Jin-Woo Park, Kwang-Bum Park, Jo-Young Suh

biomaterials 28, 2007: 3306-3313

72

2007

32

Effects of a novel calcium titanate coating on the osseointegration of blasted endosseous implants in rabbit tibiae

Jo-Young Suh, Oh-Cheol Jeung, Byung-ju Choi, Jin-Woo Park

Clin. Oral Impl. Res, 18, 2007: 362-369

74

2017

33

Genetic Expression of SaOS2 cells grown on two different Implant Surfaces - An in vitro study

Enrico Conserva, Francesco Borghi and Ugo Consolo

J Dent Oro Surg 2(1): 127.

POSTER

78

2011

1st MegaGen Poster Competition : Overall Grand Prize

100 nm : The diameter of nanotube showing good implant stability

Kwi-Dug Yun1, Mong-Sook Vang1, Hong-So Yang1, Hyun-Pil Lim1, Jung-Tae Koh1, Sang-Won Park1.

80

2011

1st MegaGen Poster Competition : Best Research Prize

3 x 3 x 121 : 3 protocols in 3 years on 121 implants

L. Dusi, S.G. Marino, N. Proserpio

82

2011

1st MegaGen Poster Competition : Best Research Prize

39 kg vs 51 kg : loading effect on implants primary stability

S.G. Marino , L. Dusi , N. Proserpio

84

2011

1st MegaGen Poster Competition : Excellence Prize

98,29% : Success Rate using MegaGen Rescue implants as an alternative

Siormpas K., Kontsiotou - Siormpa E., Efremidis I.

86

2012

2nd MegaGen Poster Competition : Overall Grand Prize

5 years : 5 years survival rates of 152 short & Super-wide implant(Rescue, MegaGen Co.)in atrophic maxillary posterior regions; A retrospective study in 118 patients.

Min Young Kim, Sung Koog Jung, Seung Yeup Lee

88

2012

2nd MegaGen Poster Competition : Best Research Prize

99,1% : Survival rates of AnyRidge implants

Jun Hong Park

90

2012

2nd MegaGen Poster Competition : Excellence Prize

5 mm △CAL : Surgical therapy of peri-implantitis with decontamination using an air-polishing device and GBR with a bovine derived xenograft - a case report

Irfan Abas, C.E. Teulings, R. Junker

92

2012

2nd MegaGen Poster Competition : Excellence Prize

5 years : A 5-years observational study of 50 Rescue implants

A. Maglione, M. Cappello, C. Allievi

94

2012

2nd MegaGen Poster Competition : Excellence Prize

3 methods : To compare the rhBMP-2 release kinetics from the implant surfaces according to different loading methods

Juri Ma, Hyeju Son, Jeongtae Koh, Jaesam Ban, Mongsook Vang, Hongso Yang, Hyunpil Lim, Gyejeong Oh, Kyunku Lee, Seongsoo Kang, Kwang Min Lee, Sangwon Park, Kwidug Yun

96

2013

3rd MegaGen Poster Competition : Overall Grand Prize

100% : Success rate using AnyRidge implants after 2 years of loading.

Siormpas K, Kontsiotou-Siormpa E, Efremidis I Kotsakis G and Mitsias ME

98

2013

3rd MegaGen Poster Competition : Best Research Prize

3 : Three-dimensional analysis for implant thread slope and angulation

H.S. JOO, Y.H. Seo, M.S. Vang, H.S. Yang, S.W. Park , H.P. Lim, K.D. Yun, W.C. Shin

100

2013

3rd MegaGen Poster Competition : Best Research Prize

99,2% : 1 year survival rates of 378 AnyRidge® implants with Xpeed surface ; A retrospective study in 156 partially edentulous patients.

Sung-Koog Jung, Yeon-Kang Jung, Seung-Yeup Lee, Kwang-Bum Park

102

2013

3rd MegaGen Poster Competition : Excellence Prize

98,9% : Survival rate up to 7 years of loading using Rescue MegaGen short wide diameter implants.

Mitsias ME, Kontsiotou- Siormpa E, Efremidis I and Siormpas K

104

2013

3rd MegaGen Poster Competition : Excellence Prize

3 : 3 different coating materials : Influence of implant abutment screw coating materials on joint stability

Woonchul Shin, Young-sun Park, Mongsook Vang, Hongso Yang, Sangwon Park, Hyunpil Lim, Kwi-Dug Yun, Hansung Joo



POSTER

- 106

2013

3rd MegaGen Poster Competition : Excellence Prize

108,13 vs 32,63 : What is the criteria for decision of proper time for prosthetics?

Youn-Kang Jung, Sung-Koog Jung, Seung-Yeup Lee, Kwang-Bum Park
- 108

2015

4th MegaGen Poster Competition : Overall Grand Prize

1,5 : 1,5 mm of Buccal Bone Width Prevents Bone Resorption: Perspective evaluation on 84 consecutive cases

Daive Farronato, Andrea Alain Orsina, Pietro Mario Pasini, Filippo Ferretti, Eleonora Pionati, Giada Goffredo, Davide Fumagalli
- 110

2015

4th MegaGen Poster Competition : Best Research Prize

100% : Success rate of the "Root Membrane" Technique using AnyRidge implants after 3 years of loading

Siormpas K, Kontsiotou- Siormpa E, Gasparatos S, Kotsakis G, Mitsias ME
- 112

2015

4th MegaGen Poster Competition : Best Research Prize

0,66mm : SHORT-TERM MARGINAL PERI-IMPLANT BONE LOSS ASSOCIATED WITH PLATFORM SWITCHED IMPLANTS: A PROSPECTIVE COMPARATIVE SPIT MOUTH STUDY.

Alessandro Rossi, David Palombo, Luigi Tagliatesta, Andrea Flora, Vincenzo Capilupi*, Matteo Chiapasco
- 114

2015

4th MegaGen Poster Competition : Excellence Prize

21 PATIENTS SINUS LIFT : SINUS LIFT CRESTAL APPROACH (MICA-KIT): TECHNICAL DESCRIPTION AND CASE SERIES

Oscar Alonso Gonzalez , Santiago Pasquín C de Sobregrau , Ramon Buenechea Imaz, Meritxell Losada Martinez,
- 116

2015

4th MegaGen Poster Competition : Excellence Prize

1 connection : 3D-planning makes it possible to design and manufacture an definitive abutment and immediate placement after implant insertion

Dr. Irfan Abas
- 118

2015

4th MegaGen Poster Competition : Excellence Prize

1 Surgery 1 Time : Whats in you're toolbox

Dr Isaac Tawil, Dr David Tawil

- 120

2016

5th MegaGen Poster Competition : Overall Grand Prize

3 : Three ways of measuring the implant primary stability: Torque, ISQ and bone density accessed by CBCT and there correlations, RCT with Anyridge implants.

RAQUEL ZITA GOMES, ANTONIO FELINO, LAURA SILVA, JOAO COIMBRA, ANDRE CORREIA, RICARDO TAVARES, MARIO VASCONCELOS
- 122

2016

5th MegaGen Poster Competition : Best Research Prize

2 years : IMMEDIATE FUNCTIONAL LOADING OF SINGLE ANYRIDGE® IMPLANTS A 2-YEAR PROSPECTIVE MULTICENTER STUDY

MANGANO , LUONGO, RAES , LENZI , ECCELLENTE , ORTOLANI , LUONGO , MANGANO
- 124

2016

5th MegaGen Poster Competition : Best Research Prize

98,40% : PDL-Mediated Immediate Implant Placement using the "Root Membrane Technique". 98,40% Success rate after 5 years of loading.

Siormpas K. , Kontsiotou-Siormpa E., Gasparatos S. , Triikka D. , Kotsakis G. , Mitsias ME.
- 126

2016

5th MegaGen Poster Competition : Excellence Prize

12 months follow-up : SINUS LIFT CRESTAL APPROACH (MICA-KIT): EVALUATION OF CRESTAL HEIGHT VARIATION ONE YEAR POST-SURGERY.

OSCAR ALONSO GONZALEZ , SANTIAGO PASQUÍN C DE SOBREGRAU, RAMON BUENECHEA IMAZ, MERITXELL LOSADA MARTINEZ
- 128

2016

5th MegaGen Poster Competition : Excellence Prize

2,3 : 2,3-fold increase in the proliferation of human gingival stem cells associated with culturing in the presence of TriCalcium Phosphate "Bone Plus-MEGAGEN" Scaffolds.

Pablo Quiroz, Isabel Benjumeda,Sergio Tapia, Carola Millán, Juan Francisco Vivanco.
- 130

2016

5th MegaGen Poster Competition : Excellence Prize

2 : 2 years follow-up results in pre-shaped titanium mesh reconstruction of bone dehiscence around implants: a prospective study

IULIAN FILIPOV , CRISTIAN ROTARU, LUCIAN CHIRILA

MEGAGEN ARTICLES

CATEGORY :
DIGITAL-IMPLANT-REGENERATION-SURFACE
P.NO : 01-33

MEGAGEN
For Lifetime Smiles

01.

Presurgical Cone Beam Computed Tomography Bone Quality Evaluation for Predictable Immediate Implant Placement and Restoration in Esthetic Zone.

Corina Marilena Cristache

Case Rep. Dent. 2017; 2017: 1096365. Published online 2017 Feb 22. doi: 10.1155/2017/1096365

01. Summary

The use of a guided surgical approach through a computerized simulation enables the implant placement to be provided with around 98% accuracy. Guided surgery is advantageous for conventional implant placement, immediate implant placement, and potential immediate provisionalisation.

02. Introduction & Methods

Nowadays, cone beam computed tomography (CBCT) systems replaced multi-slice computed tomography (MSCT) for dental treatment and planning due to many advantages offered, including a lower radiation dose to the patient, shorter acquisition times, affordable cost, better resolution, and sometimes greater details. CBCT uses isotropic voxels and, as a result, measurements are precise and considered 1:1; therefore study models and 3D printing or milling surgical templates can be fabricated with great accuracy.

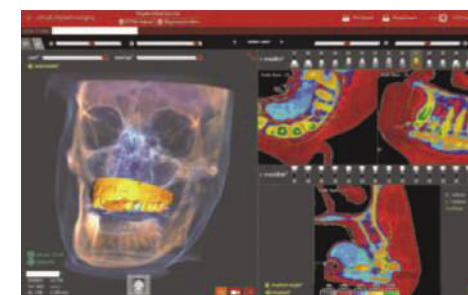31 year old woman with retained upper left primary canine tooth, agenesis of #22, permanent cusped (#23) in transposition with mesio-vestibular rotation.

To facilitate bone quality assessment the "DigitalEye" option of R2GATE treatment planning software was used. This option provides automatic conversion of CBCT gray scale in 5 basic colors, corresponding to the 256 shades of gray, from the CBCT scan, visible on computer monitors. Atraumatic extraction of the primary canine using periostomes was performed. A 10mm with 3,5mm diameter MegaGen AnyRidge (Korea) was inserted flapless, under local anesthesia, according to the planned 3D position with the use of the stereolithographic template. Eight weeks after implant surgery, after uneventful osseointegration, the provisional crown was unscrewed and an excellent healing of dento-gingival complex and papilla preservation were observed. Digital impression was performed and a CAD-CAM zirconia customized abutment and ceramic crown were manufactured according to patient's request.

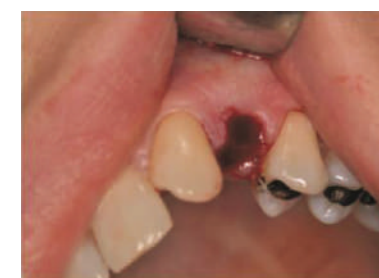03. Results

The decision of immediate implant placement and manufacturing provisional crown can rely on CBCT bone quality assessment during the pre-surgical implant-planning phase.

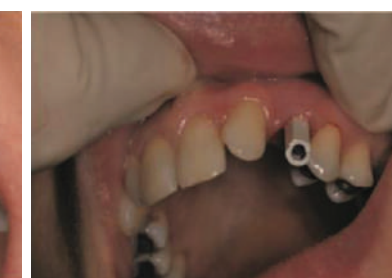
The use of CBCT gray scale automatic conversion in 5 colors and the windowing process allows the clinician for a better evaluation of bone characteristics for a precise implant planning and crown fabrication. But final decision on immediate restoration can be taken only at the time of surgery, after objective evaluation of primary implant stability.



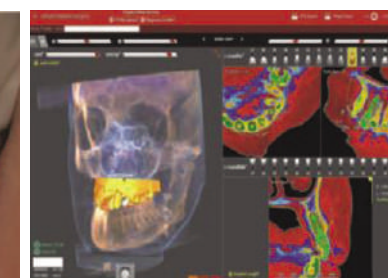
• Fig. 1, Print-screen of the treatment plan, Bone characteristics can be observed and buccal plate can be measured in R2GATE software.



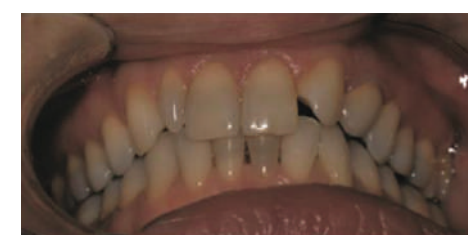• Fig. 2, Atraumatic extraction of #63



• Fig. 3, Digital impression with scannable coping screwed into the implant



• Fig. 4, CBCT at one-year follow-up. No bone resorption was noticed.



• Fig. 5, Final crown at 1-year follow-up.

02.

Implant Stability in the Posterior Maxilla :
A Controlled Clinical Trial

Raquel Zita Gomes,Mario Ramalho de Vasconcelos, Isabel Maria Lopes Guerra, Rute Alexandra Borges de Almeida, and Antonio Cabral de Campos Felino

BioMed, Research International Volume 2017 (2017), Article ID 6825213, 11 pages

01. Summary

AnyRidge Implant showed linear ISQ progression, without a significant drop of stability values within the first two months of healing. This last finding may be related to the surgical protocol adopted, but also to the macro topographical features (threads design) and to the surface of the implant used in this study, characterized by a peculiar nanotopographic design.

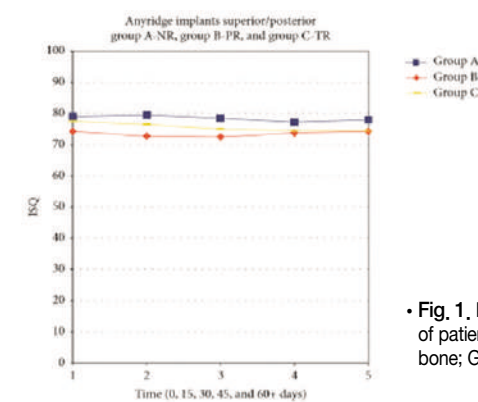
02. Introduction & Methods

The assessment of the quality of the bone structure should be considered essential, prior to implant placement. In fact, the achievement and maintenance of an adequate implant stability are fundamental prerequisites for the long-term positive outcomes of osseointegrated implants.

Patients were allocated into three groups: (A) native bone, (B) partially regenerated bone, and (C) nearly totally regenerated bone. 133 implants (AnyRidge, MegaGen) were installed in 59 patients: 55 fixtures were placed in Group A, 57 in Group B, and 21 in Group C. Insertion torque (IT) and implant stability quotient (ISQ) were measured at placement, to evaluate whether satisfactory high primary stability ($IT \geq 45N/cm$; $ISQ \geq 60$) was achieved; ISQ was measured 15, 30, 45, and 60 days after placement, to investigate the evolution to secondary stability.

03. Results

Fifty-two implants had satisfactory high primary stability ($IT \geq 45N/cm$; $ISQ \geq 60$). A positive correlation was found between all variables (IT, ISQ at $t=0$, $t=60$), and statistically higher IT and ISQ values were found for implants with satisfactory high primary stability. Significant differences were found for IT and ISQ between the groups (A, B, and C); however, no drops were reported in the median ISQ values during the healing period. The evaluation of the primary and secondary implant stability may contribute to higher implant survival/success rates in critical areas, such as the regenerated posterior maxilla.



• Fig. 1. Progression of ISQ values during the healing phase in the 3 groups of patients (Group A: non-regenerated bone; Group B: partially regenerated bone; Group C: nearly totally regenerated bone).

• Table 1. Number of observations (per variable and per group) in all 133 considered implants.

Group	A llimplants (IT, initial and final ISQ measures)	Implants with ISQ measure at 15 days	Implants with ISQ measure at 30 days	Implants with ISQ measure at 45 days
A	55	14	14	10
B	57	14	13	11
C	21	12	12	12
Total	133	40	39	33

• Table 2. Median values of ISQ measures at each time, per group (Group A : nonregenerated bone; Group B: partially regenerated bone; Group C: nearly totally regenerated bone), in implants with satisfactory high primary implants stability.

	ISQ t = 0	ISQ t = 15	ISQ t = 30	ISQ t = 45	ISQ t = 60
A	78.00	79.25	77.75	78.50	78.00
B	75.25	73.50	74.00	73.75	75.00
C	77.50	76.50	73.50	74.50	74.50

03.

Accuracy of a direct drill-guiding system with minimal tolerance of surgical instruments used for implant surgery: a prospective clinical study

Du-Hyeong Lee, Seo-Young An, Min-Ho Hong, Kyoung-Bae Jeon, Kyu-Bok Lee

J. Adv. Prosthodont. 2016 Jun; 8(3): 207-213. Published online 2016 Jun 17. doi: 10.4047/jap.2016.8.3.207

01. Summary

The direct drill-guiding implant surgery system (R2 Gate) demonstrates high accuracy in placing implants. Use of the drill shank as the guiding component is an effective way for reducing tolerance.

02. Introduction & Methods

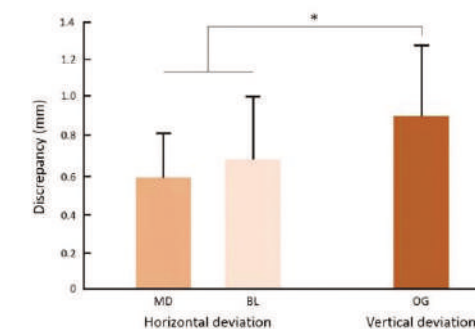
Recently, a direct drill-guiding implant surgery system with a completely limiting design was developed. R2 Gate system features shank-modified drills that use the shank portion of surgical instruments as a guiding component to limit drilling motion with little tolerance.

Eleven patients requiring implant placements in partially edentulous jaws were included in this study. 21 implants were placed in 11 consecutive patients using the direct drill-guiding implant surgery system. The stereolithographic augmentation with bone grafting were excluded from the study.

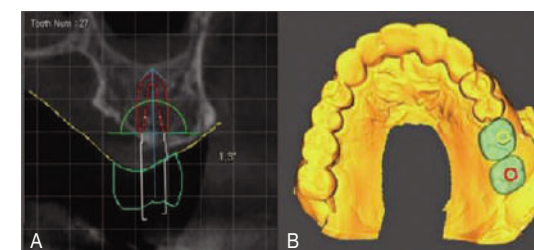
Implant surgery was performed according to the manufacturers' instructions. The stereolithographic surgical guide was fabricated using cone-beam computed tomography, digital scanning, computer-aided design and computer-assisted manufacturing, and additive manufacturing processes. After surgery, the positional and angular deviations between planned and placed implants were measured at the abutment level using implant-planning software. The Kruskal-Wallis test and Mann-Whitney U test were used to compare the deviations.

03. Results


The mean horizontal deviations were 0.593 mm (SD 0.238) mesiodistally and 0.691 mm (SD 0.344) buccolingually. The mean vertical deviation was 0.925 mm (SD 0.376) occlusogingivally. The vertical deviation was significantly larger than the horizontal deviation ($P=0.018$). The mean angular deviation was 2.024 degrees (SD 0.942) mesiodistally and 2.390 degrees (SD 1.142) buccolingually.



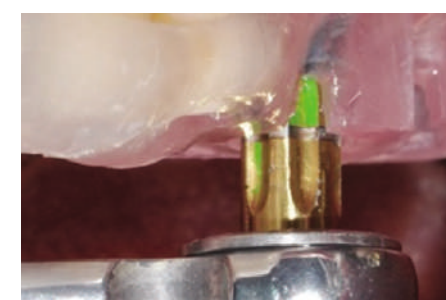• Fig. 1. Discrepancy values for horizontal and vertical deviations in three dimensions (MD: mesiodistal, BL: buccolingual, OG: occlusogingival. *Significant difference).



• Fig. 2. Implant treatment planning. (A) cross-sectional image of virtually placed implant, (B) three-dimensional image of virtual restorations.



• Fig. 3. Implant treatment planning. (A) cross-sectional image of virtually placed implant, (B) three-dimensional image of virtual restorations.



• Fig. 4. Implant placement using the ratchet and ratchet connector.

04.

Virtual Planning of 3-Dimensional Implant Position Using a Radiopaque Scanning Tray

Jong-Eun Kim, June-Sung Shim

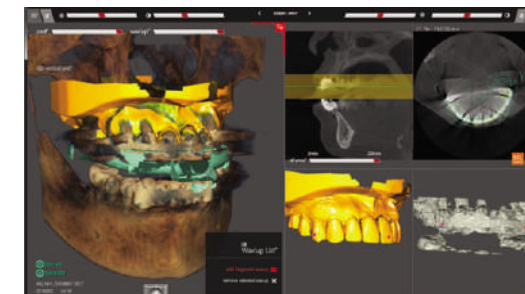The Korean Academy of Oral & Maxillofacial Implantology Vol. 20, No. 4, 2016

01. Summary

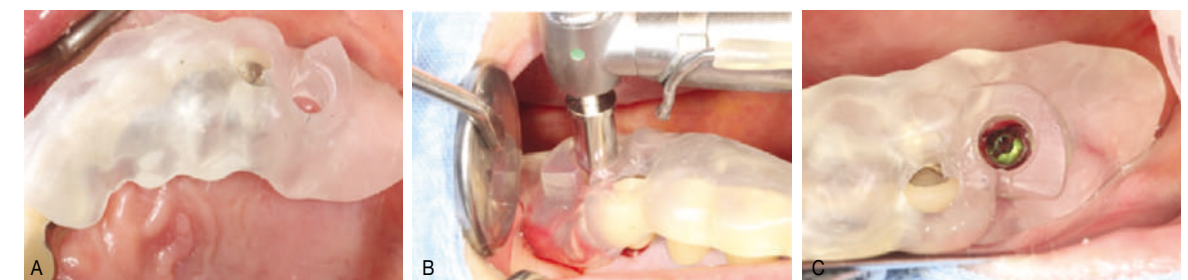Cases where it is hard to do an accurate implant guided surgery due to already delivered metallic prosthesis in all the pre-existing set of teeth, using R2 Tray as a medium in overlapping with CBCT helped planning the position of the implant and the placement itself successfully.

02. Introduction & Methods

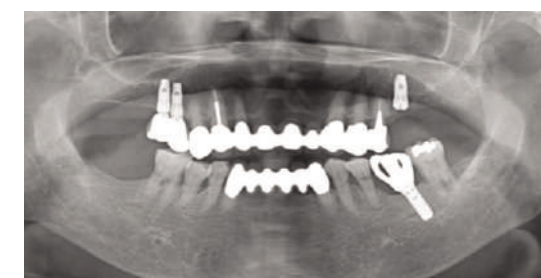Computer-guided implant surgical template is fabricated based on superimposition information between cone-beam computed tomography (CBCT) data and dental arch digital data scanned by intraoral scanner or tabletop scanner. The superimposition stage is one of the most important stage in the process of making computer-guided implant surgical template. If there are many fixed metal prostheses in the intraoral environment, superimposition process could have trouble due to metal artifact in CBCT images. This case report aimed to present computer-guided implant planning procedure using a radiopaque scanning tray to solve metal artifact problem in the patient having many metal prostheses.



• Fig. 1. Superimposition process with CBCT using outline of radiographic guide tray of combination scan data.



• Fig. 2. (A) Surgical guide prosthesis was tried in, in order to check fitness.
 (B) Implant surgery was performed with specialized surgical drill kit for implant guided surgery procedure.
 (C) It was confirmed that implant was installed in the planning position.



• Fig. 3. Panorama X-ray imaging after implant installation.

03. Results

This case was filmed after applying polyether material to the R2 Tray; the polyether material has a little bit of radiopaque property that allowed us to confirm the outer applied appearance. This helped check how the material and teeth are closely engaged through the CBCT image and since this is related to the accuracy of the surgical guide, it can be considered important.

05.

Comparative Study on Clearance between Drilling and Bushing of Various Implant Guide Systems

Ji-Man Park, Seong-Joo Heo, Eun-Jin Park

The Korean Academy of Oral & Maxillofacial Implantology Vol. 18, No. 3, 2014

01. Summary

The tolerance between bushing and drilling was significantly different among the six guide systems examined. Accordingly, the operator should pay attention to the characteristics of each system while drilling.


02. Introduction & Methods

The accuracy of an implant surgical guide system depends on the accumulation of errors from each fabrication step, and efforts to reduce the errors have been made using different strategies. The aim of this study was to examine the tolerance between drilling and bushing of various computer-guided templates and to understand the characteristics of each system.

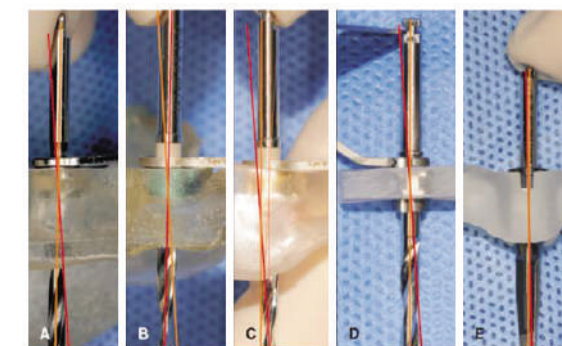
This study investigated six guide systems, including foreign brands (Simplant, NobelGuide), and Korean brands (OsstemGuide, Navisis, NeoGuide, R2GATE). Photos were taken twice while the drill was held to the left and to the right. Two photos were merged together and the angle between two axes of each drill was measured.

03. Results

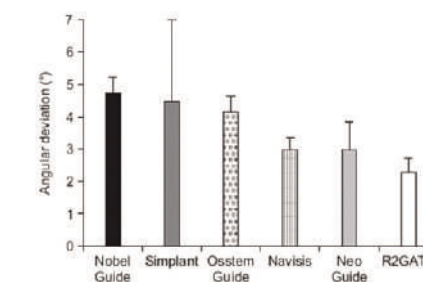
There was a difference in tolerance between bushing and drilling according to the system and drill shape. The angular deviation varied from a minimum of 0.94° to a maximum of 7.82° . When we compared the twists of the drills, the tolerance of NobelGuide and Simplant was significantly larger, while that of the R2GATE was significantly smaller than the others.



• Fig. 1. Various drills from the guide system manufactures were studied.



• Fig. 2. Difference among NobelGuide (A), OsstemGuide (B), Navisis (C), NeoGuide (D), and R2GATE (E) twist drills.



• Fig. 3. Angular deviation between twist drills and bushings of various guide template systems.

06.

Immediate Loading of Single Implants in the Anterior Maxilla: A 1-Year Prospective Clinical Study on 34 Patients

Miguel Stanley, Filipa Calheiros Braga, and Beatriz Mota Jordao

Hindawi International Journal of Dentistry Volume 2017, Article ID 8346496, 11 pages

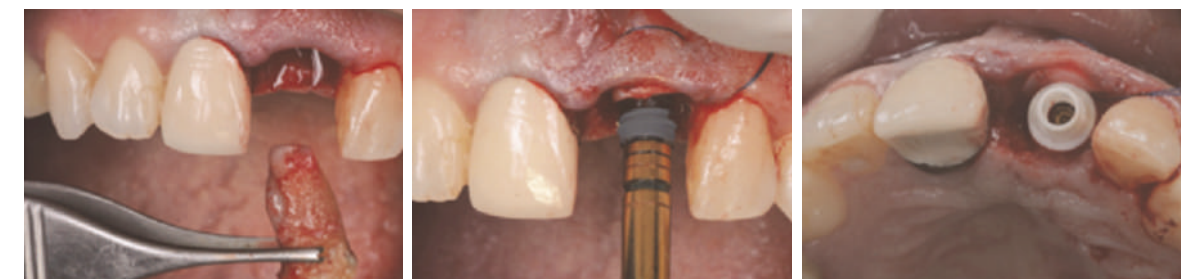01. Summary

In this prospective clinical study with a follow-up of 1 year, the immediate loading of single implants with knife-edge thread design and nanostructured calcium-incorporated surface placed in the anterior maxilla gave positive clinical outcomes, with high survival (100%) and success (95.2%) rates.

02. Introduction & Methods

The assessment of the quality of the bone structure should be considered essential, prior to implant placement. In fact, the achievement and maintenance of an adequate implant stability are fundamental prerequisites for the long-term positive outcomes of osseointegrated implants.

Over a 2-year period, all patients referred to a private clinic were considered for enrollment in this study. Inclusion criteria were single-tooth placement in post-extraction sockets or healed sites of the anterior maxilla. All implants were immediately loaded and followed for a period of 1 year after the placement of definitive crowns. The outcome measures were implant stability, survival, and success.



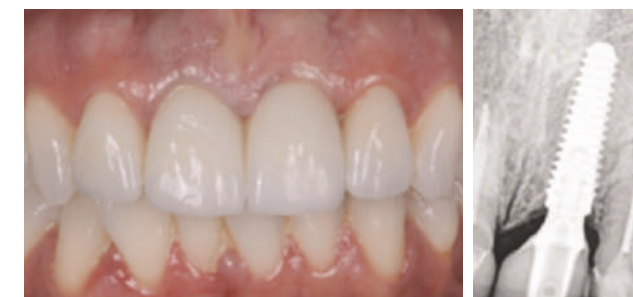• Fig. 1. The nonrestorable tooth is extracted

• Fig. 2. The implant (AnyRidge, MegaGen) is inserted slightly subcrestal and in palatal position

• Fig. 3. Immediate provisionalization. A provisional abutment is screwed on the implant

03. Results

34 patients were selected and 43 tapered implants with a knife-edge thread design and a nanostructured, calcium-incorporated surface (AnyRidge, MegaGen, Gyeongsan, Korea) were installed. Two implants were not sufficiently stable at placement ($ISQ < 60$) and were considered failed for immediate loading; 41 implants had an $ISQ \geq 60$ at placement and were immediately loaded. One year after the placement of definitive crowns, no implant failures were reported, for a survival rate of 100%. No biological complications were found, but 2 implants had their prosthetic abutments loosened: the implant success rate was 95.2%. In the present study on the immediate loading of single implants in the anterior maxilla, positive outcomes were reported, with high survival (100%) and success (95.2%) rate.



• Fig. 4. The definitive ceramic crown 1 year after the delivery.
 (a) An aesthetically pleasing result has been maintained clinically, and the patient is fully satisfied
 (b) The radiographic control confirms the stability of the hard tissues around the implant.

07.

Accuracy Evaluation of a Stereolithographic Surgical Template for Dental Implant Insertion Using 3D Superimposition Protocol

Corina Marilena Cristache, Silviu Gurbanescu

Int. J. Dent. 2017; 2017: 4292081. Published online 2017 May 7. doi: 10.1155/2017/4292081

01. Summary

The surgical template used has proved high accuracy for implant insertion. Within the limitations of the present study, the protocol for comparing a digital file (treatment plan) with post-insertion digital impression may be considered a useful procedure for assessing surgical template accuracy, avoiding radiation exposure, during post-operative CBCT scanning.

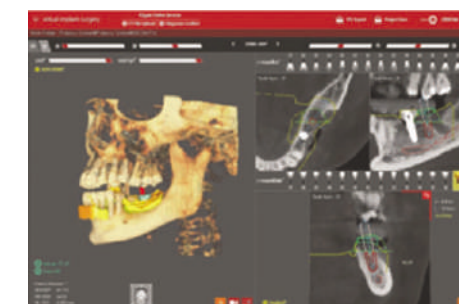
02. Introduction & Methods

Implant positioning accuracy is crucial especially when immediate restoration is intended and limited space is available and to avoid damaging the vital structures. The protocol of static surgical guidance involves several steps from data collection, to planning, surgical template manufacturing, and effective surgical placement of the implants. Errors can occur at each individual step and the final inaccuracy is the sum of all mistakes.

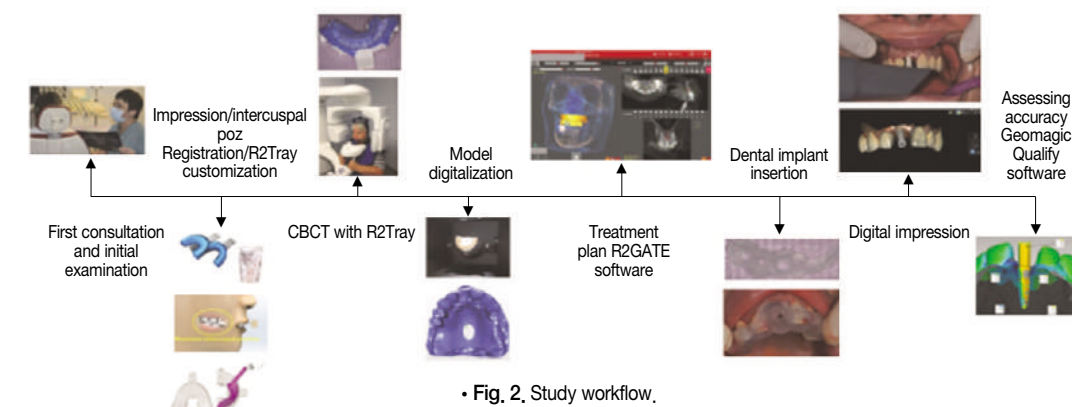
Sixty-five implants were placed in twenty-five consecutive patients with a stereolithographic surgical template. After surgery, digital impression was taken and a series of axially sliced image data were obtained and exported to a personal computer in DICOM format. DICOM files obtained from CBCT and STL files were imported in a treatment plan software R2GATE version1.0.0 (MegaGen, Gyeongbuk, Korea) and R2 Tray was used as landmark for superimposition of the scanned model and underlying bone image. All 65 implants inserted were AnyRidge (MegaGen Implant, Gyeongbuk, Korea).

03. Results

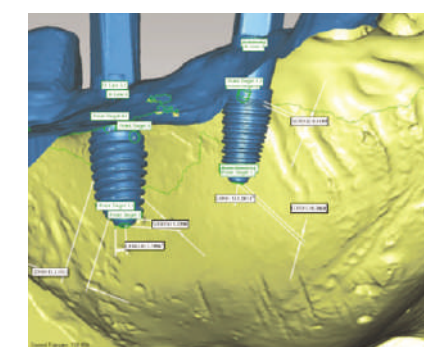
The mean (and standard deviation) of 3D error at the entry point was 0,798mm ($\pm 0,52$) and at the implant apex was 1,17mm ($\pm 0,63$) and most of the super-imposed surfaces were green mapped (error $\pm 0,0995$ mm), indicating a high accuracy level between model (treatment plan) and test (implants placed). However, differences in accuracy were noticed when analyzing implants inserted in maxilla and mandible. For the mandible, a significantly lower 3D error was observed at entry point $p = 0,037$, at implant apex $p = 0,008$, and also in angular deviation $p = 0,030$ when comparing the 3D error of the implants inserted in the maxilla. No significant difference in accuracy between maxilla and mandible was noticed regarding vertical deviation at entry point ($p=0,314$).



• Fig. 1, Planned implant insertion in R2GATE software.



• Fig. 2, Study workflow.



• Fig. 3.
Measurement of 3D accuracy of the planned (reference) and effective implant insertion(test), * represents degree symbol (°) as it measures an angle.

08.

Dental implants with internal versus external connections : 5-year post-loading results from a pragmatic multicenter randomized controlled trial

Marco Esposito, Hassan Maghaireh, Roberto Pistilli, Maria Gabriella Grusovin, Sang Taek Lee, Anna Trullenque-Eriksson, Federico Gualini

Eur. J. Oral Implantol, 2016;9 Suppl, 1(2):129-41.

01. Summary

Within the limitations given by the difference in neck design and platform switching between External Connection and Internal Connection implants (EZ Plus, MegaGen Implant, Gyeongbuk, South Korea), 5-year post-loading data did not show any statistically significant differences between the two connection types, therefore clinicians could choose whichever they preferred.

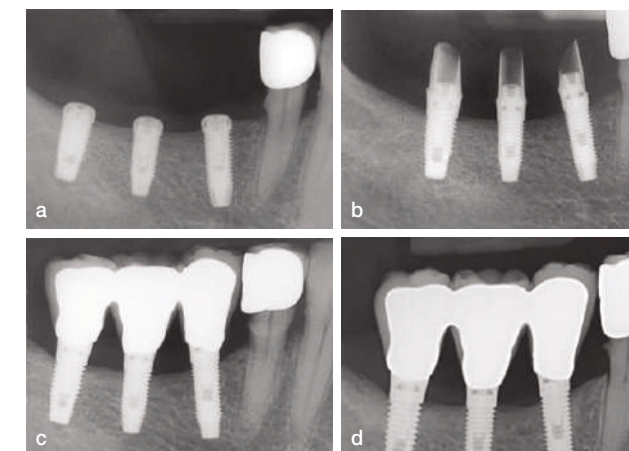
02. Introduction & Methods

Screw-retained connections can be divided into two major groups: external and internal connections. The external connection is characterized by a mechanism on the top of the screw to block rotation movements which favor unscrewing. The internal connection is characterized by the presence of the connection mechanism inside the implant body. The aim of this pragmatic multicenter RCT of parallel group design was to evaluate advantages and disadvantages of identical implants with internal or external connections.

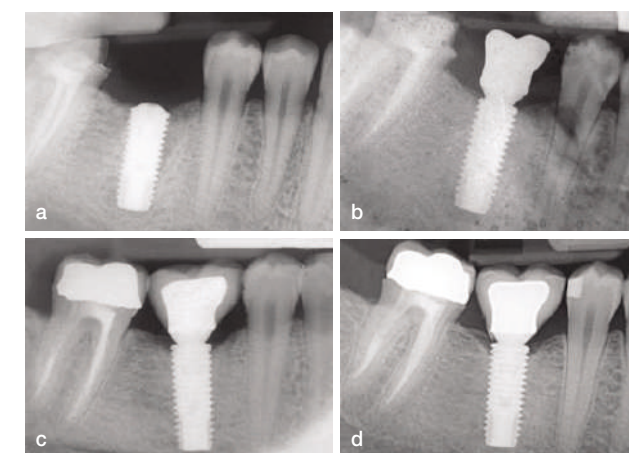
One hundred and twenty patients with any type of edentulism (single tooth, partial and total edentulism), requiring one implant-supported prosthesis were randomly allocated in two equal groups to receive either implants with an external connection (EC) or implants of the same type with an internal connection (IC) (EZ Plus, MegaGen Implant, Gyeongbuk, South Korea), at four centers. Due to slight differences in implant design and components, IC implants were platform-switched with EC were not. Patients were followed for 5 years after initial loading. Outcome measures were prosthesis/implant failures, any complication, marginal bone level changes and clinician preference, assess by blinded outcome assessors.

03. Results

Sixty patients received 96 EC implants and 60 patients received 107 IC implants. Three patients dropped out with four EC implants and five patients with ten IC implants, but all remaining patients were followed up to 5-year post-loading. One prosthesis supported by EC implants and two by IC implants failed ($P = 0.615$, difference = -0.02 , 95% CI: -0.08 to 0.04). One EC implant failed versus three IC implants in two patients ($P = 0.615$, difference = -0.02 , 95% CI: -0.08 to 0.04). Ten complications occurred in 10 EC patients versus nine complications in 9 IC patients ($P = 1.000$, difference = 0.01 , 95% CI: -0.13 to 0.15). There were no statistically significant differences for prosthesis and implant failures and complications between the different connection types. Five years after loading, there were no statistically significant differences in marginal bone level estimates between the two groups (difference = 0.14 mm, 95% CI: -0.28 to 0.56 , P (ancova) = 0.505) and both groups lost bone from implant placement in a statistically significant way: 1.13 mm for the EC implants and 1.21 mm for the IC implants. Two operators had no preference and two preferred IC implants.



• Fig. 1. Sequence of periapical radiographs of one of the patients treated with EZ Plus implants, with an external connection (EC) included in this study (courtesy of Dr Pistilli): a) implant placement; b) initial loading; c) 1 year after loading; d) 5 years after loading.



• Fig. 2. Sequence of periapical radiographs of one of the patients treated with EZ Plus implant, with an internal connection (IC) included in this study (courtesy of Dr Pistilli): a) implant placement; b) initial loading; c) 1 year after loading; d) 5 years after loading. Please note that IC implants had to be platform-switched due to the implant design.

09.

Short (6-mm) dental implants versus sinus floor elevation and placement of longer (≥10-mm) dental implants: a randomized controlled trial with a 3-year follow up.

Bechara S, Kubilius R, Veronesi G, Pires JT, Shibli JA, Mangano FG.

Clin. Oral. Implants Res. 2016 Jul 12. doi: 10.1111/clr.12923

01. Objectives

To investigate whether short (6-mm) dental implants could be an alternative to sinus floor elevation (SFE) and placement of longer (≥10-mm) implants in the posterior maxilla.

02. Materials and methods

Over a 3-year period, all patients presenting with partial edentulism in the posterior maxilla were considered for inclusion in this randomized controlled trial. Patients were randomly chosen either to receive short (6-mm) implants (test group [TG]) or to undergo SFE with simultaneous placement of standard-length (≥10-mm) implants (control group [CG]). SFE was performed using the lateral technique. In both groups, tapered implants (AnyRidge, MegaGen, Gyeongbuk, South Korea) were placed. All implants were loaded after 4 months of healing. At each annual follow-up session, clinical and radiographic parameters were assessed. Primary outcomes were implant survival, stability (measured with the implant stability quotient [ISQ]), marginal bone loss (MBL), and complications; secondary outcomes were patient satisfaction and treatment time and cost.

03. Results

Thirty-three patients were assigned to the TG and 20 to the CG. Forty-five implants were inserted in each group. At 3 years, implant survival rates were 100% and 95.0% for the TG and CG, respectively; this difference was not statistically significant ($P = 0.38$). The mean ISQ values of the TG and CG did not differ at placement (68.2 vs. 67.8, $P = 0.1$), at delivery of the final restoration (69.5 vs. 69.4, $P = 0.9$), and after 1 year (71.0 vs. 71.5, $P = 0.1$); at 3 years, the CG had a significantly higher mean ISQ than the TG (72.4 vs. 71.6, $P = 0.004$). Mean MBL was significantly higher in the CG than in the TG, both at 1 year (0.14 mm vs. 0.21 mm, $P = 0.006$) and at 3 years (0.20 mm vs. 0.27 mm, $P = 0.01$). A few complications were reported. Surgical time and cost were significantly higher in the CG than in the TG ($P < 0.0001$). Patient satisfaction was high in both groups.

04. Conclusions

In this randomized controlled trial, results for short (6-mm) implants were similar to those for longer (≥10-mm) implants in augmented bone. Short implants might be preferable to SFE, because the treatment is faster and less expensive. Long-term randomized controlled trials are required to confirm these results.

Time	Control group		Test group		P*	P†
	Mean (95% CI)	Δ (95% CI)‡	Mean (95% CI)	Δ (95% CI)‡		
At placement	67.8 (67.4–68.2)	–	68.2 (67.9–68.6)	–	0.1	–
At delivery of final restoration	69.4 (69.0–69.8)	1.6 (1.2–2.0)	69.5 (69.1–69.8)	1.2 (0.8–1.6)	0.9	0.2
At 1 year	71.5 (71.1–71.9)	2.1 (1.7–2.5)	71.0 (70.6–71.4)	1.5 (1.1–1.9)	0.1	0.1
At 3 years	72.4 (72.0–72.8)	0.9 (0.4–1.3)	71.6 (71.2–71.9)	0.6 (0.2–1.0)	0.004	0.3
1-year change from placement	–	3.7 (3.3–4.1)	–	2.8 (2.3–3.2)	–	0.002
3-year change from placement	–	4.6 (4.1–5.0)	–	3.3 (2.9–3.7)	–	<0.0001

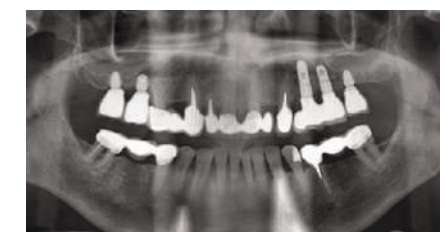Mean (95% CI) from a repeated-measures model with ISQ at placement as covariate, allowing for a nonzero correlation between implants in the same object.
*P value for testing the hypothesis of no difference in ISQ mean values between control and test groups at each time period.
†P value for testing the hypothesis of no difference in ISQ mean change values between control and test groups.
‡Incremental change in mean ISQ from a repeated-measures model with ISQ at placement as covariate.

• Table 1. Mean (95% CI) values of ISQ at placement, at delivery of final restoration, and after 1 and 3 years of follow-up in the control and in the test group, and over time trend assessment

	Yes, I am fully satisfied (%)	Yes, I am quite satisfied (%)	No, I am not satisfied (%)	P*
Do my implant-supported restoration/s function well?				
Test group†	29 (90.6)	3 (9.4)	0 (0.0)	0.7
Control group	17 (85.0)	3 (15.0)	0 (0.0)	
Do I feel secure biting/chewing on my implant-supported restoration/s?				
Test group†	29 (90.6)	3 (9.4)	0 (0.0)	0.7
Control group	17 (85.0)	3 (15.0)	0 (0.0)	
Am I pleased with the esthetic result?				
Test group†	27 (84.4)	5 (15.6)	0 (0.0)	0.5
Control group	15 (75.0)	5 (25.0)	0 (0.0)	
Can I clean my implant-supported restoration/s well?				
Test group†	30 (93.8)	2 (6.2)	0 (0.0)	0.6
Control group	18 (90.0)	2 (10.0)	0 (0.0)	
Am I satisfied with the treatment?				
Test group†	29 (90.6)	3 (9.4)	0 (0.0)	0.7
Control group	17 (85.0)	3 (15.0)	0 (0.0)	
Would I undergo this treatment again?				
Test group†	29 (90.6)	3 (9.4)	0 (0.0)	0.7
Control group	17 (85.0)	3 (15.0)	0 (0.0)	
Would I recommend this treatment to a relative/friend?				
Test group†	29 (90.6)	3 (9.4)	0 (0.0)	0.7
Control group	17 (85.0)	3 (15.0)	0 (0.0)	
Is the cost of treatment justified?				
Test group†	27 (84.4)	5 (15.6)	0 (0.0)	0.03
Control group	11 (55.0)	9 (45.0)	0 (0.0)	

*Fisher's exact test.
†Data not available for one patient in the test group.

• Table 2. Patient satisfaction in the two groups



• Fig. 1. Test group, Panoramic radiograph 3 years after implant placement.

10.

The effect of implant macro-thread design on implant stability in the early post-operative period: a randomized, controlled pilot study

Jeffrey J. McCullough, Perry R. Klokkevold

Clin. Oral Implants Res. 2016 Oct 3. doi: 10.1111/clr.12945.

01. Introduction

Available literature suggests there is a transient drop in implant stability from approximately week 0 to week 3-4 as a result of peri-implant bone remodeling as it transitions from a primary, mechanical stability to a secondary, biological stability. Research investigating the influence of macro-thread design on this process is scant.

02. Aim

The specific aim of this study was to evaluate the role of macro-thread design on implant stability in the early post-operative healing period using resonance frequency analysis (RFA).

03. Material and methods

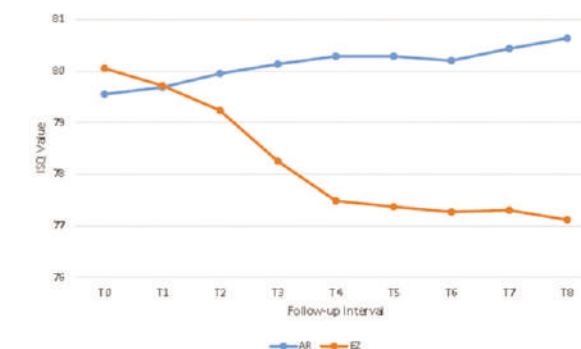
Seven patients, each missing at least two posterior teeth in the same arch, were included in the study. Three patients qualified for four implants resulting in a total of 10 matched pairs. All sites were healed (>6 months), non-grafted sites with sufficient bone to place implants. Each site in a matched pair was randomly assigned to receive either a control (Megagen EZ Plus Internal; EZ) or test (Megagen AnyRidge; AR) implant. The test implant incorporates a novel thread design with a wide thread depth and increased thread pitch. RFA was used to determine implant stability quotient (ISQ) values for each implant at the time of placement and weekly for the first 8 weeks.

04. Results

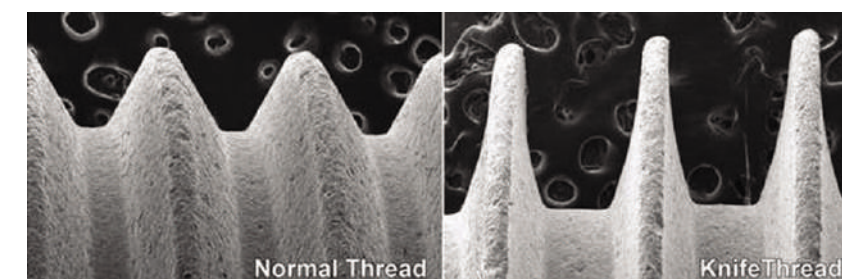
Implants consistently achieved a relatively high insertion torque (30-45 N/cm) and high initial ISQ value (79.8 ± 1.49). Baseline ISQ values for test (AR; 79.55 ± 1.61) and control (EZ; 80.05 ± 1.37) implants were similar. A general pattern of stability from baseline through all eight follow-up evaluations was observed for the test implants. A pattern of decreasing ISQ values was observed for the control implants across the early follow-up evaluations up to week four, where the value plateaued. There was a statistically significant main effect due to implant type ($P < 0.01$) and a statistically significant interaction between implant type and time ($P < 0.01$), indicating that the test and control implants performed differently at certain time points.

05. Conclusions

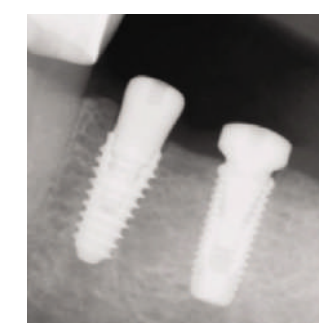
Within the limitations of this study, macro-thread design appears to play a role in implant stability in the early post-operative healing period as assessed by RFA. These findings may have important implications related to immediate or early loading protocols.



• Fig. 1. Mean ISQ at baseline (T0) and 8 weekly follow-up evaluations



• Fig. 2. Microscopic view of a standard V-shape thread design (EZ Plus Internal; left) and the novel knife thread design (AnyRidge; right)



• Fig. 3. Radiographic appearance of test (left) and control (right) implants

11.

Immediate Loading of Single Implants: A Two-Year Prospective Multicenter Study

Mangano C, Raes F, Lenzi C, Eccellente T, Ortolani M, Luongo G, Mangano F.

Int. J. Periodontics Restorative Dent. 2017 Jan/Feb;37(1):69-78. doi: 10.11607/prd.2986.

01. Summary

Immediate functional loading of single implants with AnyRidge could represent a safe and effective procedure, characterized by high survival rates (97.6%), low incidence of biologic complications, and rather limited peri-implant marginal bone loss (MBL, 0.37 ± 0.22 mm).

02. Introduction & Methods

Immediate loading is greatly successful in complex rehabilitations that provide for the placement of numerous implants splinted between themselves, as shown by numerous clinical studies. On the other hand, there is less evidence in the literature regarding the immediate loading of implant-supported single crowns, especially in the posterior region.

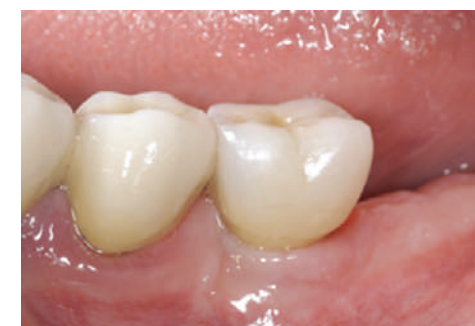The purpose of this prospective multicenter study with 2 years follow-up was therefore to assess survival, complications, and peri-implant marginal bone loss (MBL) of single implants placed in healed sites and in post-extraction sockets and subjected to immediate functional loading.

Inclusion criteria were single-tooth placement in post extraction sockets or fully healed sites, and sufficient bone height and width to place an implant of at least 3.5×10.0 mm. All implants were functionally loaded immediately after placement and followed for 2 years.

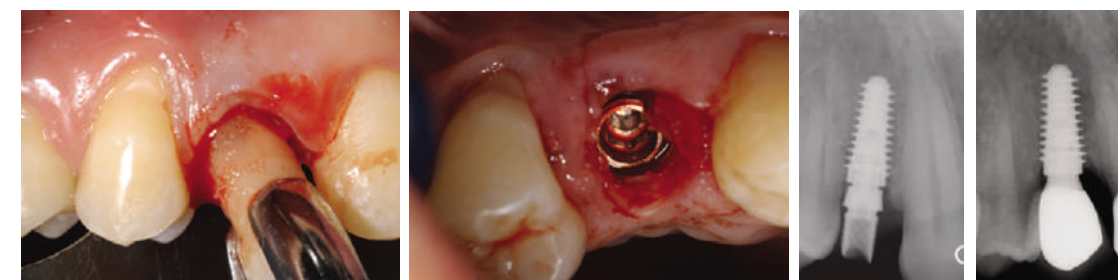03. Results

A total of 57 implants (38 maxilla, 19 mandible) were placed in 46 patients (23 men, 23 women, aged 18~73 years).

Of these, 10 implants were placed in post-extraction sockets. One implant failed, in a healed site, giving a patient-based overall 2-year survival rate of 97.6%. The incidence of biologic complications was 1.8%; prosthetic complications amounted to 7.5%. The peri-implant MBL was 0.37 ± 0.22 mm (healed sites: 0.4 mm ± 0.22 ; post-extraction sockets: 0.3 mm ± 0.22).



• Fig. 1. At 3 months after implant placement, the final metal-ceramic crown was delivered.



• Fig. 2. Immediate implant placement procedure in the anterior maxilla

• Table 1. Peri-implant MBL Between Groups at Different Time Periods

	Baseline-3 mo	Baseline-1 y	Baseline-2 y
Healed sites			
Patients (n)	35	33	31
Mean (SD) MBL (mm)	0.23 (0.18)	0.36 (0.21)	0.4 (0.22)
Median MBL (mm)	0.2	0.4	0.4
95% CI	0.18-0.28	0.29-0.43	0.33-0.47
Extraction sockets			
Patients (n)	10	10	10
Mean (SD) MBL (mm)	0.20 (0.18)	0.22 (0.20)	0.3 (0.22)
Median MBL (mm)	0.25	0.25	0.35
95% CI	0.09-0.31	0.10-0.34	0.17-0.43
All sites			
Patients (n)	45	43	41
Mean (SD) MBL (mm)	0.22 (0.17)	0.33 (0.22)	0.37 (0.22)
Median MBL (mm)	0.2	0.4	0.4
95% CI	0.18-0.26	0.27-0.39	0.31-0.43

MBL = marginal bone loss.

12.

Immediate, early (6 weeks) and delayed loading (3 months) of single implants: 4-month post-loading from a multicenter pragmatic randomized controlled trial.

Esposito M, Siormpas K, Mitsias M, Bechara S, Trullenque-Eriksson A, Pistilli R.

Eur. J. Oral Implantol. 2016;9(3):249-260

01. Summary

All loading strategies were successful with no significant difference between them, although immediate and early loading achieved similar results in a shorter period of time. If treatment duration is an issue for the patient, then immediate loading could be a preferable choice, if implants are placed with a sufficient insertion torque.

02. Introduction & Methods

It has been recommended to keep the implants load-free during the bone healing process to minimize the risk of soft tissue encapsulation. This traditional approach requires longer treatment periods and according to the procedures used, a second surgical intervention may be needed to uncover submerged implants to allow abutment connection. Early attempts to load implants earlier than the traditional protocols were associated with increased failure rates. Nowadays, implants are commonly loaded immediately and early, particularly in fully edentulous mandibles with good bone quality.

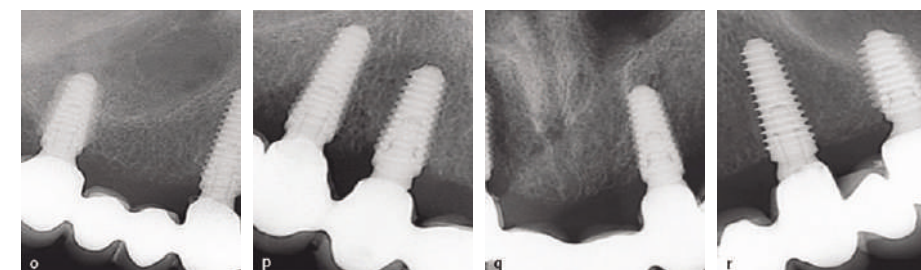
Eighty-one patients (27 requiring single implants, 27 requiring partial fixed prostheses and 27 requiring total fixed cross-arch prostheses) were randomized in equal numbers in three private practices to immediate loading (27 patients), early loading (27 patients) and conventional loading (27 patients) according to a parallel group design with three arms. To be immediately or early loaded, implants had to be inserted with a torque superior to 40Ncm. AnyRidge Xpeed (MegaGen Implant, Gyeong-buk, South Korea) threaded titanium implants with an internal connection were used. Implants were initially loaded with provisional prostheses and replaced after 4 months by definitive ones. Outcome measures were prosthesis and implant failures and complications.

03. Results

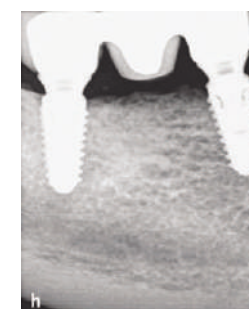
No prosthesis or implant failures and complications were reported for any of the patients up to 4 months after loading.



• Fig. 1. Immediate Loading Group: Periapical radiograph at delivery of crown 4 months after immediate loading



• Fig. 2. Early loading group: Periapical radiographs at delivery of the definitive prosthesis, 4 months after initial loading.



• Fig. 3. Conventional group: Periapical radiograph, 4 months after initial loading

13.

Immediate Loading of Tapered Implants Placed in Post extraction Sockets and Healed Sites

Han CH, Mangano F, Mortellaro C, Park KB

J. Craniofac. Surg. 2016 Jul;27(5):1220-7.

01. Summary

Immediately loaded implants placed in post extraction and healed sites achieved similar positive outcomes, with high survival rates, excellent stability, and no complications. Because adequate primary stability is considered a prerequisite for the success of immediate loading protocols, the use of AnyRidge may be beneficial, as it can guarantee an excellent initial stability, with high IT and ISQ values.

02. Introduction & Methods

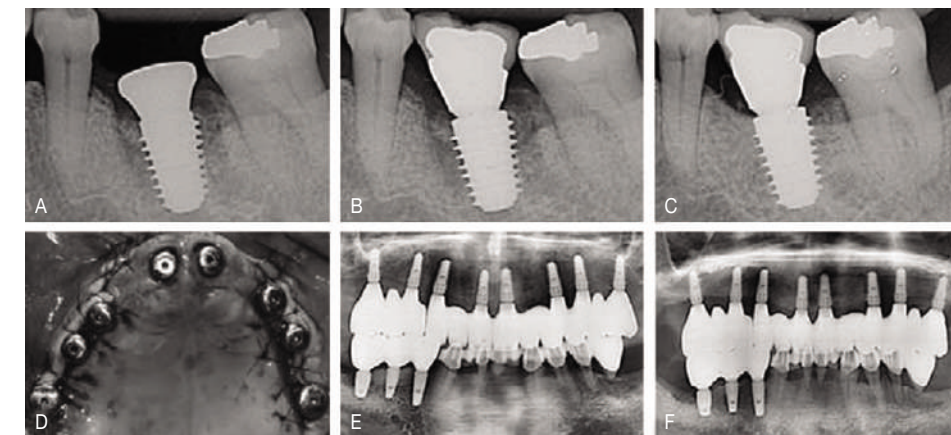
Immediate loading is greatly successful in complex rehabilitations that provide for the placement of numerous implants splinted between themselves, as shown by numerous clinical studies. On the other hand, there is less evidence in the literature regarding the immediate loading of implant-supported single crowns, especially in the posterior region.

The purpose of this prospective multicenter study with 2 years follow-up was therefore to assess survival, complications, and peri-implant marginal bone loss (MBL) of single implants placed in healed sites and in post-extraction sockets and subjected to immediate functional loading.

Inclusion criteria were single-tooth placement in post extraction sockets or fully healed sites, and sufficient bone height and width to place an implant of at least 3.5×10.0 mm. All implants were functionally loaded immediately after placement and followed for 2 years.

03. Results

Thirty implants were placed in post-extraction sockets of 17 patients, and 32 implants were placed in healed sites of 22 patients. There were no statistically significant differences in ISQ values between the 2 groups, at each assessment. In total, 60 implants (96.8%) had an IT 45 and an ISQ 70 at placement and at each follow-up control: all these implants were successfully loaded. Only 2 implants (1 in a post-extraction socket and 1 in a healed site, 3.2%) could not achieve an IT 45Ncm and/or an ISQ 70 at placement or over time: accordingly, these were considered failed for stability, as they could not be subjected to immediate loading. One of these 2 implants, in a healed site of a posterior maxilla, had to be removed, yielding an overall 1-year implant survival rate of 98.4%. No complications were reported. No significant differences were reported between the 2 groups with respect to implant failures and complications.



• Fig.1. Single implant placed in the mandible and multiple implants placed in the maxilla(A-C) & Intraoperative clinical photograph of 8 implants placed in the maxilla, (D-F)

14.

Fixed Full Arches Supported by Tapered Implants with Knife-Edge Thread Design and Nanostructured, Calcium-Incorporated Surface: A Short-Term Prospective Clinical Study

Soheil Bechara, Algirdas Lukosiunas, Giorgio Andrea Dolcini, Ricardas Kubilius

BioMed Research International Volume 2017 (2017), Article ID 4170537, 11 pages

01. Summary

Fixed Full Arches (FFA) restorations supported by implants with a knife-edge thread design and nanostructured, calcium-incorporated surface are successful in the short term, with high survival and low complication rates.

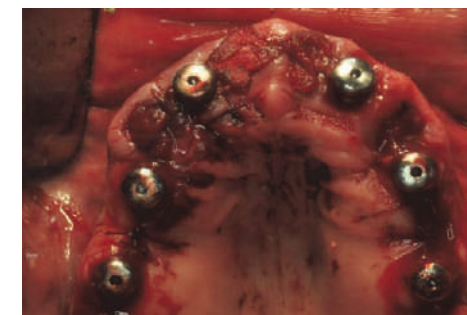
02. Introduction & Methods

New implant designs (macro topographies) that maximize the primary stabilization in difficult contexts (e.g., sites with poor bone density, like the posterior maxilla, or post extraction sockets) have been proposed, as well as new implant surfaces (micro- or even Nano topographies) able to accelerate deposition of new bone onto the fixture and, therefore, secondary stabilization.

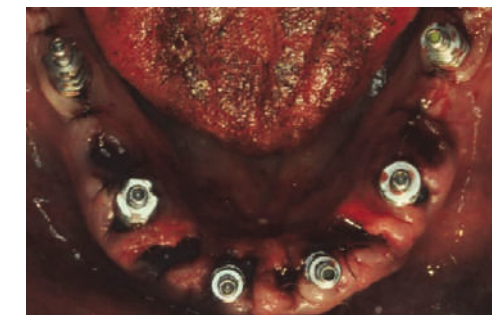
Between January 2013 and December 2015, all patients referred for implant-supported FFA restorations were considered for enrollment in this study. All patients received implants with a knife-edge thread design and nanostructured calcium-incorporated surface (AnyRidge, MegaGen, South Korea) were restored with FFA restorations and enrolled in a recall program. The final outcomes were implant survival, peri-implant bone loss, biologic/prosthetic complications, and “complication-free” survival of restorations.

03. Results

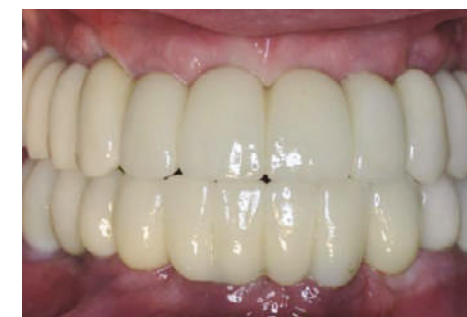Twenty-four patients were selected. Overall, 215 implants were inserted (130 maxilla, 85 mandible), 144 in extraction sockets and 71 in healed ridges. Thirty-six FFAs were delivered (21 maxilla, 15 mandible): 27 were immediately loaded and 9 were conventionally loaded. The follow-up ranged from 1 to 3 years. Two fixtures failed, yielding an implant survival rate of 95.9% (patient-based). A few complications were registered, for a “complication-free” survival of restorations of 88.9%.



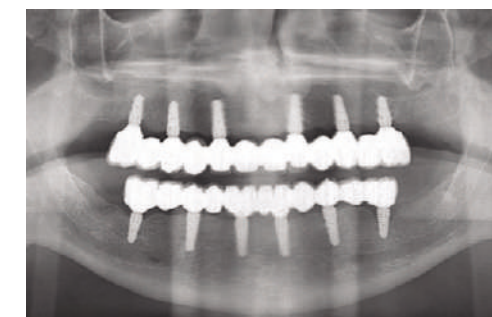• Fig. 1, 6 implants placed to support a maxillary FFA restoration



• Fig. 2, 6 implants placed in the mandible



• Fig. 3, The final metal-ceramic FFAs at the 3-year follow-up control.



• Fig. 4, Panoramic radiograph of the FFAs at the 3-year follow-up control.

15.

Early bone formation around immediately loaded implants with nanostructured calcium-incorporated and machined surface: a randomized, controlled histologic and histomorphometric study in the human posterior maxilla

Francesco Guido Mangano & Giovanna Iezzi, Jamil Awad Shibli, Jefferson Trabach Pires, Giuseppe Luongo, Adriano Piattelli, Carlo Mangano

Clin. Oral Invest (2017). doi:10.1007/s00784-017-2061-y.

01. Summary

Immediately loaded NCI temporary implants (Xpeed AnyRidge) in human posterior maxilla presented statistically significantly higher BIC% compared to MA implants.

02. Introduction & Methods

Since titanium and its alloys exhibit bone-bonding bioactivity when a certain kind of thin ceramic layer is grown on their surface via simple chemical and heat treatments, various nanostructured calcium-incorporated implant surfaces have been introduced. Among these, there are surfaces treated with discrete crystal deposition of calcium phosphates, surfaces obtained through ion-beam assisted deposition of calcium ions, and surfaces enriched with calcium ions through hydrothermal methods.

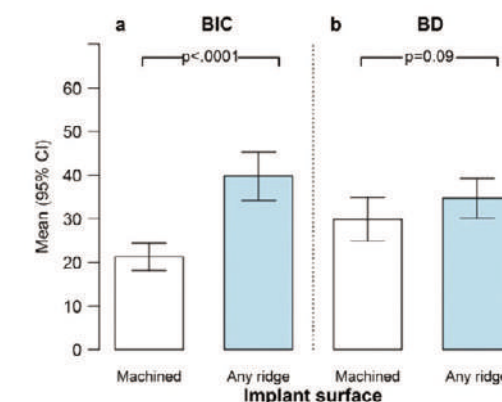
Fifteen fully edentulous patients (six males; nine females; mean age 57.9 ± 6.7 years) were selected for this study. Each patient was installed with two temporary transmucosal implants, with different surfaces: one NCI (test) and one MA (control) implant. All temporary implants were placed in the posterior maxilla, according to a split-mouth design, to help to support an interim complete maxillary denture. After 8 weeks, all temporary transmucosal implants were retrieved for histologic/histomorphometric evaluation.

The bone-to-implant contact (BIC%) and the bone density (BD%) were calculated. The Wilcoxon matched-pairs signed-rank test was used to evaluate differences (BIC%, BD%) between the surfaces. The level of significance was set at 0.05.

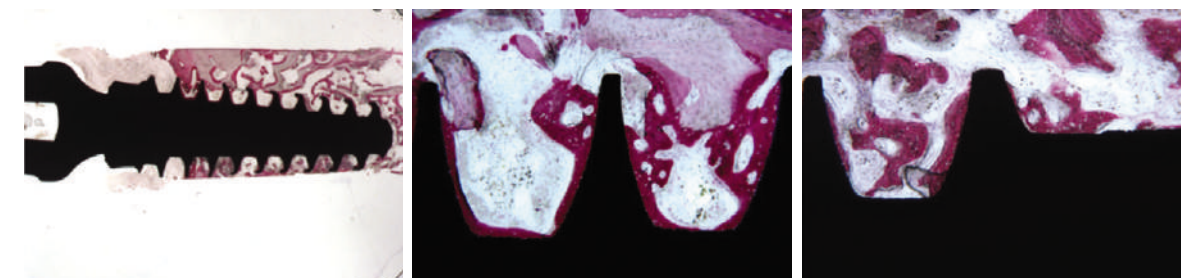
03. Results

Eight weeks after placement, 24 clinically stable implants (12 test, 12 control) were subjected to histologic/histomorphometric evaluation.

A statistically significant difference was found between the two surfaces with regard to BIC% ($p < 0.001$), while no significant difference was found with regard to BD% ($p = 0.09$).



• Fig. 1. Histomorphometric results with MA and NCI implants: bone-to-implant contact (BIC%) and bone density (BD%)



• Fig. 2. Nanostructured calcium-incorporated (NCI) implant (test). Magnification x 12 & 40

16.

Early Bone Formation around Immediately Loaded Transitional Implants Inserted in the Human Posterior Maxilla: The Effects of Fixture Design and Surface

Carlo Mangano, Jamil Awad Shibli, Jefferson Trabach Pires, Giuseppe Luongo, Adriano Piattelli, Giovanna Iezzi

Biomed Res Int. 2017;2017:4152506. doi: 10.1155/2017/4152506. Epub 2017 Feb 9.

01. Summary

In the histologic/histo-morphometric study in the human posterior maxilla, immediately loaded implants with a knife-edge thread design and nanostructured calcium incorporated surface increased the peri-implant endosseous healing properties, when compared with immediately loaded implants with a self-tapping thread design and sandblasted surface.

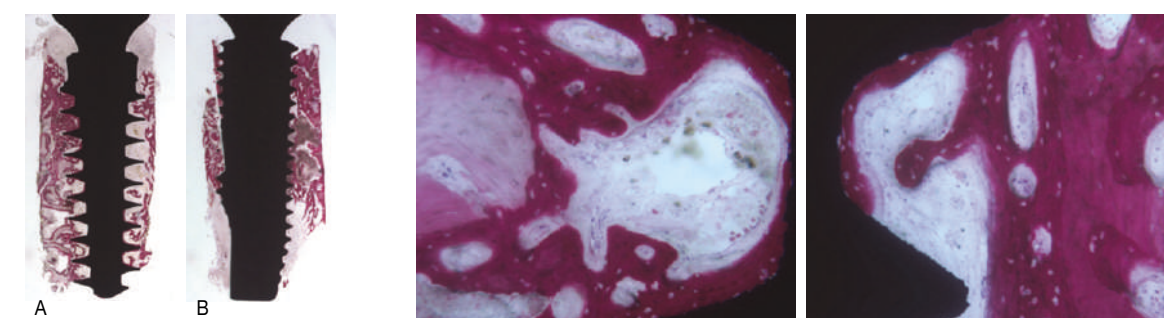
02. Introduction & Methods

The influence of the macro- and micro/nanostructure of the implant on the success of osseointegration and in particular on the first healing phases of bone is now a subject of great interest for both researchers and clinicians; the best way to assess the influence of design and implant surface on bone healing is certainly the histological and histo-morphometric analysis of the interface between bone and implant.

Ten totally edentulous subjects received two transitional implants: one tapered implant with knife-edge threads/nanostructured calcium-incorporated surface (test: AnyRidge, MegaGen, Gyeongbuk, South Korea) and one cylindrical implant with self-tapping threads/sandblasted surface (control: EZ Plus, MegaGen). The implants were placed according to a split-mouth design and immediately loaded to support an interim complete denture; after 8 weeks, they were removed for histologic/histo-morphometric analysis. The bone-to-implant contact (BIC%) and the bone density (BD%) were calculated. The Wilcoxon test was used to evaluate the differences.

03. Results

With test implants, a mean BIC% and BD% of 35.9(±9.1) and 31.8(±7.5) were found. With control implants, a mean BIC% and BD% of 29.9(±7.6) and 32.5(±3.9) were found. The mean BIC% was higher with test implants, but this difference was not significant ($p = 0.16$). Similar BD% were found in the two groups ($p = 0.9$).

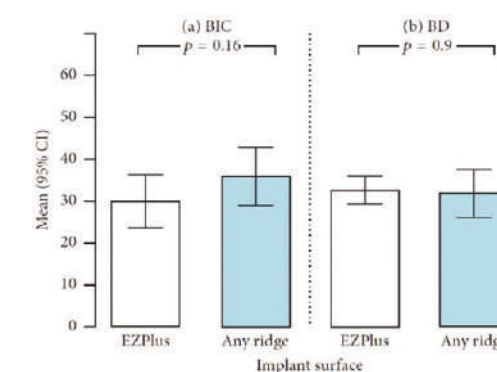


• Fig. 1. (A) Test Implant, Newly formed trabecular bone surrounded the whole implant perimeter.

• Fig. 2. Test Implant, The implant thread was lined by newly formed bone and an intense osteoblastic activity was still evident

• Fig. 3. Control Implant, Part of the implant thread was surrounded by newly formed bone and not yet mineralized osteoid matrix.

(B) Control Implant, The density of the bone tissue was different along the implant perimeter ranging from a more compact bone in the coronal portion to a very trabecular bone in the apical areas.



• Fig. 4. Histomorphometric results with EZPlus and Anyridge implants: bone-to-implant contact (BIC%) and bone density (BD%).

17.

Soft Tissue Stability around Single Implants Inserted to Replace Maxillary Lateral Incisors: A 3D Evaluation

F. G. Mangano, F. Luongo, G. Picciocchi, C. Mortellaro, K. B. Park, and C. Mangano

International Journal of Dentistry Volume 2016 (2016), Article ID 9393219, 9 pages

01. Summary

The superimposition of the 3D surface models revealed an excellent peri-implant soft tissue stability in both groups of patients, with minimal changes registered along time.

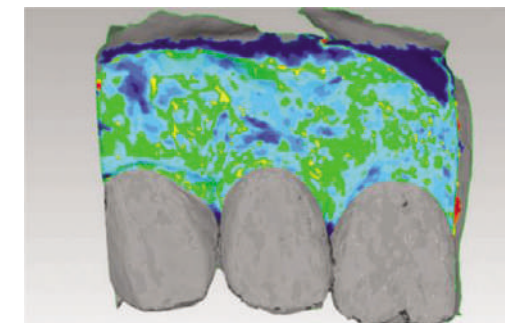
02. Introduction & Methods

Various surgical techniques have been proposed for placing of implants in the anterior maxilla. Amongst them, we should mention the immediate placement of implants in post extraction sockets, early implant placement in sites. The aim of this study was to compare the stability of peri-implant soft tissues around single implants positioned in the anterior maxilla, over time, with two different surgical protocols (immediate implants versus conventional implants), using an innovative 3D technique.

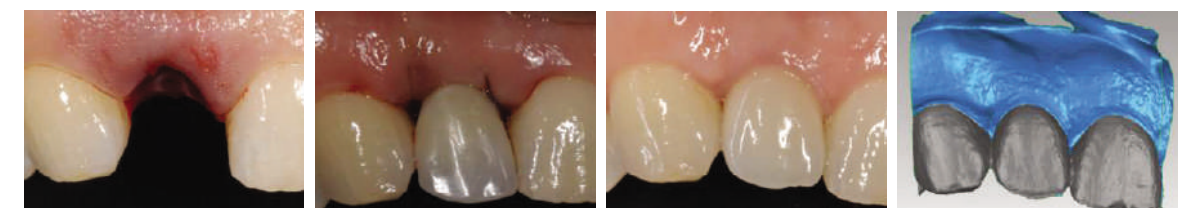We have used reverse-engineering software for the superimposition of 3D surface models of the dentogingival structures, obtained from intraoral scans of the same patients taken at the delivery of the final crown (S1) and 2 years later (S2). The assessment of soft tissues changes was performed via calculation of the Euclidean surface distances between the 3D models, after the superimposition of S2 on S1; color maps were used for quantification of changes. The bone-to-implant contact (BIC%) and the bone density (BD%) were calculated. The Wilcoxon matched-pairs signed-rank test was used to evaluate differences (BIC%, BD%) between the surfaces. The level of significance was set at 0,05.

03. Results

Twenty patients (8 males, 12 females) were selected, 10 with a failing/non-restorable lateral incisor (test group: immediate placement in post-extraction socket) and 10 with a missing lateral incisor (control group: conventional placement in healed ridge). Each patient received one AnyRidge. The superimposition of the 3D surface models taken at different times (S2 over S1) revealed a mean (\pm SD) reduction of 0,057 mm (\pm 0,025) and 0,037mm (\pm 0,020) for test and control patients, respectively. This difference was not statistically significant ($p = 0,069$).



• Fig. 1, Immediate implant placement in post extraction socket (test group) of an adult female patient (34 years old) : overlapping of digital images (S2 over S1)



• Fig. 2, Immediate implant placement in post extraction socket (test group) of an adult female patient (34 years old)

18.

The effect of the thread depth on the mechanical properties of the dental implant.

Sun-Young Lee, Sung-Jun Kim, Hyun-Wook An, Hyun-Seung Kim, Dong-Guk Ha, Kyung-Ho Ryo, Kwang-Bum Park

J. Adv. Prosthodont, 2015;7:115-21

01. Summary

The Knife Thread had higher mean insertion torque values but not lower compressive strength. The Knife Thread had a mechanical stability. Implants with deeper thread depth may increase the primary stability in areas of poor quality bone without decreasing mechanical strength.

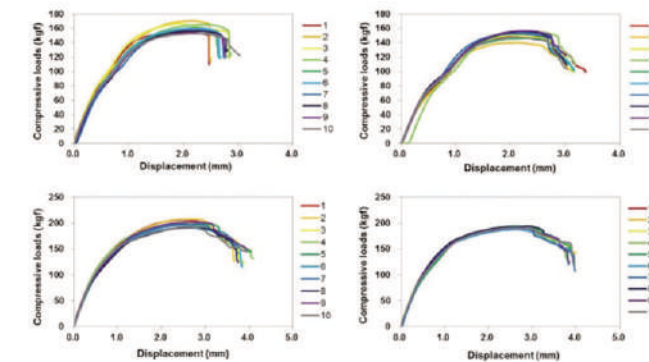
02. Introduction & Methods

Ti implants with a deeper thread depth provide a larger surface area and have an advantage in areas of poor quality bone by increasing stability. Ti implants with deeper thread depths may increase loads on and mechanical interlocking with poor quality bone. Although several studies have measured the mechanical stability through stress distribution in Ti implants with various thread depths by FEA, to our knowledge, no mechanical studies investigating the effects of the thread depth of dental implants on enhancing primary stability have been published. This study aimed to evaluate the effect of implant thread depth on primary stability in low density bone by mechanically.

AnyRidge implants which had various lengths, diameters, and thread depths roughened by grit-blasting were used in this study. The insertion torque was measured by inserting Ti implants with different thread depths into solid rigid polyurethane blocks (Sawbones) with three different bone densities (0.16 g/cm³, 0.24 g/cm³, and 0.32 g/cm³). The insertion torque value was evaluated with a surgical engine. The static compressive strength was measured with a universal testing machine (UTM) and the Ti implants were aligned at 30° against the loading direction of the UTM. After the static compressive strength test, the Ti implants were analyzed with a Measurescope.

03. Results


Ti implants with deeper thread depth showed statistically higher mean insertion torque values ($P < 0.001$). Groups A and group B had similar maximum static compressive strengths, as did groups C and D ($P > 0.05$). After the static compressive strength, the thread shape of the Ti implants with deeper thread depth did not show any breakage but did show deformation of the implant body and abutment. This difference was not statistically significant ($p = 0.069$).



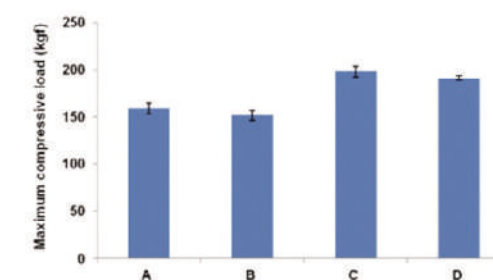
• Fig. 1. Immediate implant placement in post extraction socket (test group) of an adult female patient (34 years old) : overlapping of digital images (S2 over S1)



• Fig. 2. Photographs of four different Ti implants (a) Group A, (b) Group B, (c) Group C, (d) Group D



• Fig. 3. (a) The failure mode of group A (A), group B (B), group C (C), and group D (D) after the static compressive strength tests. The deformation was observed in the implant body and the abutment but not the threads. (b) The thread morphology of group C (A) and group D (B) after the static compressive strength tests. Breakage was not observed in the threads in the Ti implants with deeper threads.



• Fig. 4. The maximum compressive strengths of four different Ti implants. Data is expressed as the mean \pm SD (n=10). There were no significant differences between A and B or C and D ($P > 0.05$).

19.

The 10.6 μ m SuperPulse CO2 laser may alleviate the late implant failure linked to tissue tension

Jack T. Krauser, Peter Vitruk

Published: 2015 in Implant Practice US 8 (5), 30-35

01. Summary

The physics of laser tissue interaction, the considerable amount of peer-reviewed literature on uses of the CO2 laser in implant dentistry, and our own clinical experience confirm our choice of the CO2 laser as the surgical tool for soft tissue tension release, frenectomies, and vestibular extensions.

02. Introduction & Methods

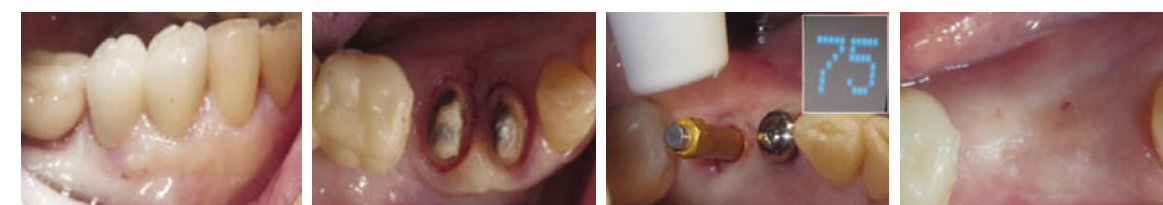
CO2 lasers have been used and studied in many areas of implant dentistry. For example, the CO2 laser is effective for creating flaps, incisions for a sinus lift, stage II implant uncovering, treatment of peri-implantitis, removal of gingival hyperplasia, epulis, fibromas, graft donor site hemostasis, and so on. The CO2 laser allows the clinician to address such critical aspects of implant therapy as the extraction site sterilization, excess cement removal troughing for digital impression, and muscle pull release. All of the above is important for long-term success of implants.

A 75-year-old female patient presented for recurrent caries in the lower left premolars Nos. 20 and 21, underneath crowns. In addition, the teeth had weak coronal structure. Since they deemed unstable for long-term survival, it was decided to extract them and replace them with two single implants.

Six weeks after extraction, the patient returned for a flapless implant placement. Six weeks after implant placement (the healing phase), the patient came in for the implant crowns loading. However, horizontal rotation of the labial and buccal tissue revealed tension created by the movable mucosa very close to the implants. This was due to the narrow zone of attached gingival mucosa. It became apparent that the encroaching movable mucosa and the close buccal frenum insertion, both exerted tension on the peri-implant tissue, especially noticeable when lip or cheek were manipulated. This created potential for tissue recession and could eventually facilitate the implants' failure. It was decided to perform a CO2 laser frenectomy/vestibuloplasty to alleviate the tension and possibly increase the width of attached gingiva.

03. Results

Healing progressed well. No signs of swelling or inflammation were noted. The patient did not express any complaints during the postoperative period. The 4-week follow-up visit showed beautifully healed tissue with no scarring. The recovery was uneventful. Two implant crowns in place and stable soft tissue. Traction applied coronally with a perio probe demonstrates the lack of frenum pull or mucosal tension at the site



• **Fig. 1.** Pre-op clinical view of crowns on the lower left premolars Nos. 20 and 21 from the buccal side. Note an encroaching thick frenum inserted high into the papilla. This frenal attachment pulled on the gingival margin and exerted tension

• **Fig. 2.** Occlusal view with the crowns taken off. Teeth with recurrent caries and weak coronal structure deemed unstable for long-term survival. They required extraction followed by two single implants

• **Fig. 3.** 6 weeks after the extraction, Local anesthesia administered for a flapless approach.

• **Fig. 4.** Second ISQ reading of the same implant driven to its intended depth



• **Fig. 5.** AnyRidge Implant placement in the extraction site & check ISQ value

20.

Immediate implant placement in the esthetic zone utilizing the “root membrane” technique: clinical results up to 5 years post-loading.

Siormpas KD, Mitsias ME, Kotsiotou-Siormpa E, Garber D, Kotsakis GA.

Int J Oral Maxillofac Implants, 2014 Nov-Dec;29(6):1397-405

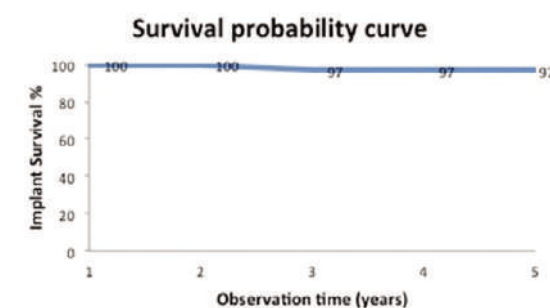
01. Summary

The intentional retention of the buccal aspect of the root with its periodontal apparatus during immediate implant placement can lead to predictable and sustainable osseointegration of EZ-plus placed in the maxillary anterior region of healthy adults.

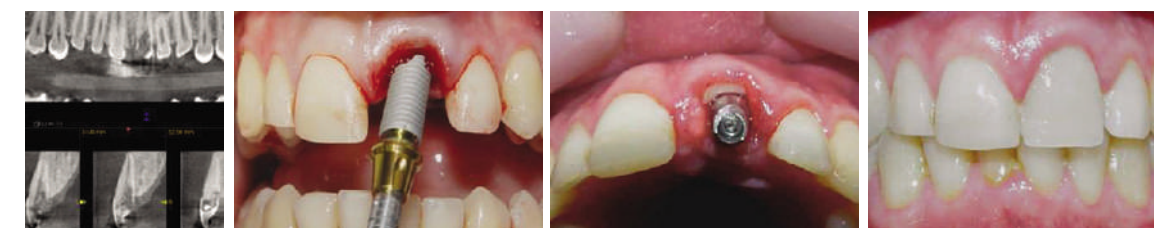02. Introduction & Methods

The aim of this retrospective case series was to evaluate the feasibility of this approach in a clinical practice setting and to report longitudinal data on survival of implants placed with the use of this innovative technique.

A retrospective case series of implants placed with the “root membrane” technique in the maxillary anterior region of adult patients was conducted. Clinical and radiographic analysis was performed to assess implant success and evaluate the survival of the retained root fragment based on pre-determined criteria. A Kaplan - Meier survival analysis was utilized to estimate the 5 year survival rate of implants placed with this technique.



• Fig. 1, 5 year Kaplan Meier survival curve estimation



• Fig. 2, Root membrane technique procedure with EZ-Plus Implant on aesthetic zone

03. Results

Data from forty-six patients (median follow-up time: 40 months, range: 24-60 months) each lending one implant site were reported in this study. All implants successfully maintained osseointegration at the end of the follow-up period for a 100% cumulative survival rate, based on clinical and radiographic criteria. Radiographic examination revealed very good crestal bone stability with mean crestal bone loss on the mesial and distal aspect of the implants estimated to be $0.18\text{mm} \pm 0.09$ and $0.21\text{mm} \pm 0.09$, respectively. The only complication noted in this patient cohort was apical root resorption of a single retained root fragment that did not interfere with the osseointegration of the implant.

21.

The management of immediate implant placement to optimize aesthetic outcome in the anterior maxilla

Howard Gluckman, Jonathan Du Toit

INTERNATIONAL DENTISTRY - AFRICAN EDITION VOL. 4, NO. 4; 48-57

01. Summary

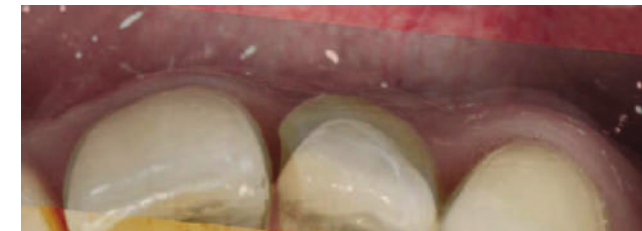Following tooth extraction the implant surgeon may select between various implant placement timing and loading protocols. Ideally these are to be determined prior to extraction, be it immediate, early, or late placement. Immediate implant placement even in the aesthetic zone is a literature supported treatment modality with success comparable to alternative placement protocols. Meticulous restorative treatment planning of a tooth destined for extraction is essential. Selecting the appropriate implant and techniques may preserve and ensure natural aesthetics. Utilizing the patient's own tooth crown can better provisionalize the implant with a 'walk out as you walk in' result.

02. Introduction & Methods

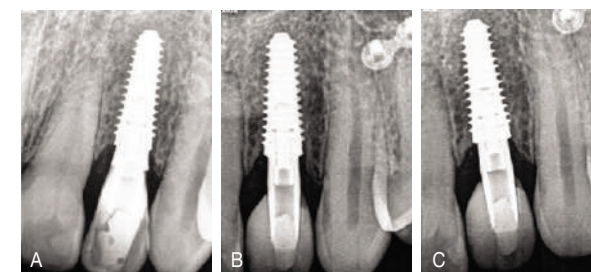
A 35 year old healthy male patient presented with a main complaint of a mobile tooth. A history of trauma was unclear. Clinical examination noted an asymptomatic tooth 22 with a Class III mobility and soft tissue inflammation. A preoperative cone beam computed tomography (CBCT) scan demonstrated significant external resorption of tooth 22 with surrounding bone loss. Clinical examination and photographs identified a high lip-line with a high aesthetic value. The tooth was indicated for extraction and the patient's primary desire was to have the edentulous space rehabilitated with a fixed prosthesis. The ITI SAC Assessment Tool classified the case as complex, with treatment planned for immediate implant placement following extraction of tooth 22, a connective tissue graft of the facial aspect by tunnel technique, and immediate provisionalization with the patient's own tooth. The aim was to provide a near identical and immediate tooth replacement, as well as to maximally support the peri-implant tissues. These would be assessed by radiographic and photographic documentation of the treatment.

03. Results

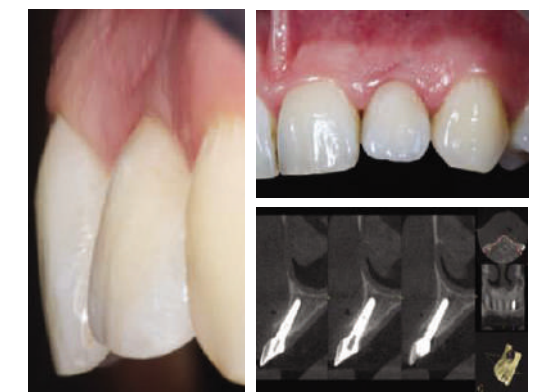Meticulous restorative treatment planning of a tooth destined for extraction is essential. Selecting the appropriate implant and techniques may preserve and ensure natural aesthetics. Utilizing the patient's own tooth crown can better provisionalize the implant with a 'walk out as you walk in' result.



• Fig. 1. Before and after incisal views of the facial contours digitally overlaid.



• Fig. 2. (A) Radiograph at day of implant placement; (B) At 4 months follow up with final restoration, (C) At 6 months follow up, Note chronologically the development of the bone, to eventually grow over the implant table.



• Fig. 3. Positive support of the peri-implant tissues.

22.

New possibilities - avoiding bone grafting with short implants.

Soheil Bechara, Kwang Bum Park, Ričardas Kubilius, Algirdas Lukošius

IDT June 2012 17:20

01. Summary

Short implants (5 mm) can be successfully loaded in maxillary bone with a residual height of 4-6mm, but their long-term prognosis is unknown. The results from our cases are promising. Treatment according to this suggested protocol could make rehabilitation with dental implants a more acceptable procedure for the patients because of lower morbidity, shorter treatment time and lower cost.

02. Introduction & Methods

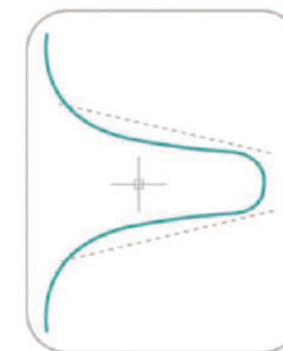
The use of short implants with deep threads is a predictable treatment method for an implant restoration, even in difficult anatomical situations, to avoid complicated augmentation procedures.

2 patients were received AnyRidge Implant with short length. The deep threads generate a significant increase in the surface area and provide a very strong mechanical connection between bone and implant.

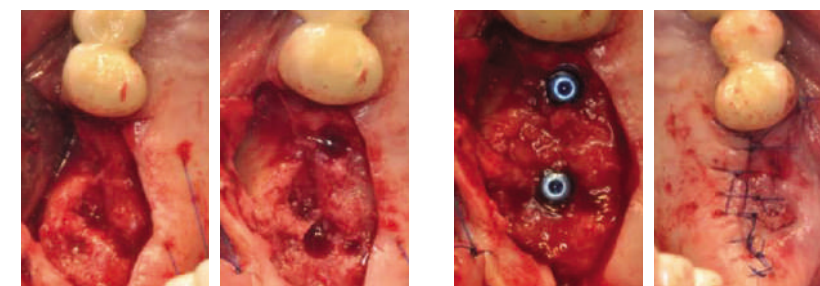
This factor can simplify the treatment for many patients presenting with vertical bone deficiency and allow more general dentists to perform implant surgeries on patients presenting with similar cases. In these case reports the implants were placed in the posterior maxilla, and only engaged in the residual jaw bone by 3-4mm.

03. Results

In both cases, successful rehabilitation was obtained with a minimal intervention. This minimally invasive protocol reduced both surgical trauma and treatment time in this challenging clinical situation. The implants (6mm short AnyRidge) were placed without any sinus augmentation, and were engaged only 3-5mm in the ridge bone.

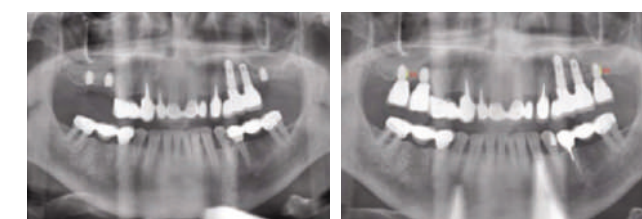


• **Figure 1** : Short implants with deep threads are designed to offer increased cutting efficiency during insertion, excellent initial stability, increased resistance to compressive forces, minimised occurrence of shear forces, and higher bone-implant contact (BIC)



• **Figures 2a and 2b** : Osteotomy preparation using a single trephine. The bone from the trephine measured about 3mm in length

• **Figures 3a and 3b** : Anyridge implants (5 x 6mm) placed



• **Figure 4** : Postoperative panoramic X-ray

• **Figure 5** : One year after loading. No marginal bone loss, good stability of the prosthesis, and a good functional and aesthetic result

23.

Effect of XPEED on Ti implants with deep threads

Sun-Young Lee, Dong-Jun Yang, Shinil Yeo, Hyun-Wook An, Sung Jun Kim, Won Mi Choi, Kwang-Bum Park

Key Engineering Materials Vols. 493-494 (2012) pp. 442-446.

01. Summary

We found that the Ti implants with XPEED® surfaces showed a similar surface morphology and surface roughness to those of the Ti implants with RBM surfaces. The Ti implants with XPEED® surfaces significantly enhanced the removal torque and the BIC %. The Ti implants with XPEED® surfaces may be shorten healing time of bone by improving osseointegration of Ti implants with deep threads.

02. Introduction & Methods

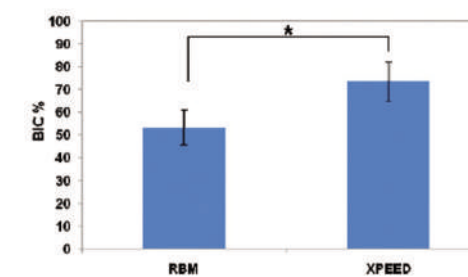
Thread geometry is an important factor that gets an effect on implant initial stability and osseointegration. Thread geometry such as thread shape, face angle, and thread pitch contributes the distribution of stresses around the implant. Deeper thread depth has an advantage in area of softer bone because of the wider surface area in contact with surrounding bone. We used the Ti implants with deep threads and investigated osseointegration of the implants with resorbable blast media (RBM) surfaces produced by grit-blasting or XPEED® surfaces by coating of the nano-structured calcium.

The Ti implants with deep threads had a thread diameter of 4.0 mm, a length of 5.0 mm and a thread depth of 1.0 mm. The Ti implants were hydrothermally treated in a mixed solution containing 2 mM CaO and 0.2 M NaOH at 180°C for 2 hrs. Ten adult male New Zealand White Rabbits weighing 3.5 - 4kg were used. A set of three control implants (implants with RBM surfaces) and a set of three experimental implants (implants with XPEED® surfaces) were randomly placed in the right legs and left legs (two implants in the tibia and one implant in the femur) The implants with RBM surfaces (n = 30) and the implants with XPEED® surfaces (n = 30) were implanted with the recommended torque.


03. Results

All implants in the implantation site were observed to have no histological inflammation at the bone-implant boundary. The mean BIC % was $53.2 \pm 7.7\%$ for the Ti implants with RBM surfaces and $73.4 \pm 8.7\%$ for the Ti implants with XPEED® surfaces. The BIC % of the Ti implants with XPEED® surfaces was significantly enhanced compared to the Ti implants with RBM surfaces ($p < 0.05$).

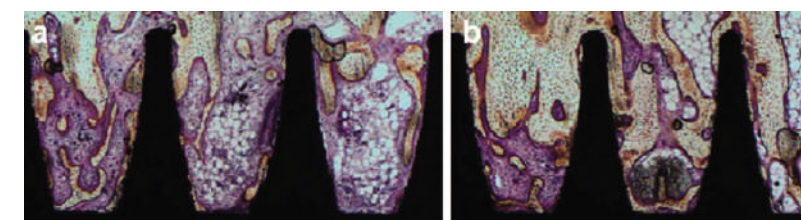
This result is consistent with previous report showing that the Nano-structured calcium-incorporated surfaces enhance osseointegration [12,13]. These results suggests that XPEED® surfaces improve the osseointegration of Ti implants with deep threads.



• Fig. 1. Mean percentage of the bone-to implant contact (BIC%) in first three threads of Ti implants at 4 weeks after implantation in rabbit femurs.



• Fig. 2. Scanning electron microscope of the Ti implants with RBM surfaces (a,b,c) and the Ti implants with XPEED surfaces (d,e,f) at magnifications of x1000 (a,d), x3000 (b,e), and x30,000 (c,f).



• Fig. 3. Histological sections of the Ti implants with RBM surfaces (a) and the Ti implants with XPEED surfaces (b) 4 weeks after implantation in rabbit femurs. Magnification of x100 (stained with Villaneueva stain) (*p < 0.05).

24.

The cytocompatibility and osseointegration of the Ti implants with XPEED surface.

Sun-Young Lee, Dong-Jun Yang, Shin-il Yeo, Hyun-Wook An, Kyung-Ho Ryoo, Kwang-Bum Park

COIR-Feb-11-OR-2079.R2

01. Objectives

This study evaluated cytocompatibility and osseointegration of the titanium (Ti) implants with resorbable blast media (RBM) surfaces produced by grit-blasting or XPEED® surfaces by coating of the nanostructured calcium

02. Material and methods

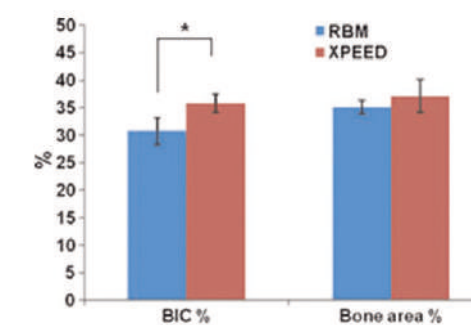
Ti implants with XPEED® surfaces were hydrothermally prepared from Ti implants with RBM surfaces in a solution containing alkaline calcium. The surface characteristics were evaluated by using a scanning electron microscope (SEM) and surface roughness measuring system. Apatite formation was measured with SEM after immersion in modified-simulated body fluid and the amount of calcium released was measured by inductively coupled plasma optical emission. The cell proliferation was investigated by MTT assay and the cell attachment was evaluated by SEM in MC3T3-E1 pre-osteoblast cells. Thirty implants with RBM surfaces and 30 implants with XPEED® surfaces were placed in the proximal tibiae and in the femoral condyles of 10 New Zealand White rabbits. The osseointegration was evaluated by a removal torque test in the proximal tibiae and by histomorphometric analysis in the femoral condyles 4 weeks after implantation.

03. Results

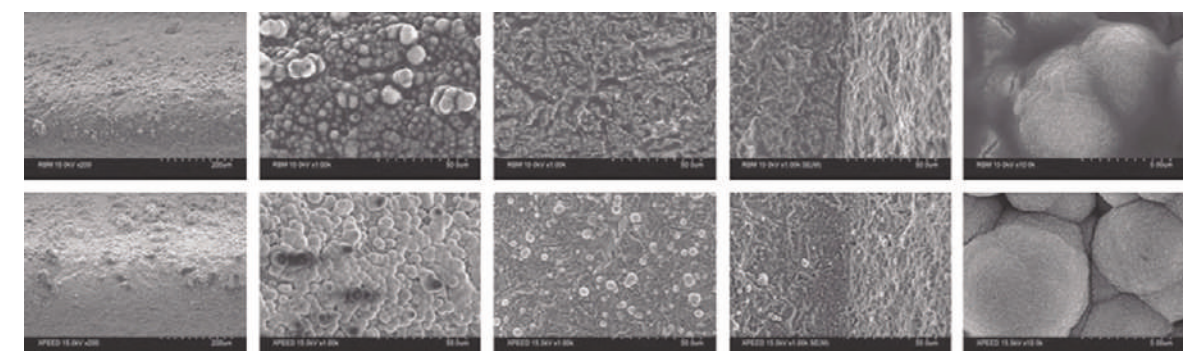
The Ti implants with XPEED® surfaces showed a similar surface morphology and surface roughness to those of the Ti implants with RBM surfaces. The amount of calcium ions released from the surface of the Ti implants with XPEED® surfaces was much more than the Ti implants with RBM surfaces ($P < 0.05$). The cell proliferation and cell attachment of the Ti implants showed a similar pattern to those of the Ti implants with RBM surfaces ($P > 0.1$). Apatite deposition significantly increased in all surfaces of the Ti implants with XPEED® surfaces. The removable torque value ($P = 0.038$) and percentage of bone-to-implant contact (BIC%) ($P = 0.03$) was enhanced in the Ti implants with XPEED® surfaces.

04. Conclusion

The Ti implants with XPEED® surfaces significantly enhanced apatite formation, removal torque value, and the BIC%. The Ti implants with XPEED® surfaces may induce strong bone integration by improving osseointegration of grit-blasted Ti implants in areas of poor quality bone.



• Fig. 1. Mean percentage of the bone-to-implant contact (BIC%) and bone area in all threads of Ti implants at 4 weeks after implantation in rabbit femurs. The BIC% was enhanced slightly in the Ti implants with XPEED® surfaces ($35.8 \pm 1.7\%$) compared with the Ti implants with RBM surfaces ($30.7 \pm 2.4\%$). No significant enhancement was observed in the percentage of the bone area between the Ti implants with RBM surfaces ($37.1 \pm 1.3\%$) and the Ti implant with XPEED® surfaces ($39.5 \pm 3.0\%$). (* $P < 0.05$).



• Fig. 2. Scanning electron microscope images of the Ti implants with RBM surfaces (a, b, c, d, e) and the Ti implants with XPEED® surfaces (f, g, h, i, j) incubated in m-SBF for 13 days. Implants with XPEED® surfaces showed more apatite formation over the surface than the other implants.

25.

Recent Changes of Dental Implant Design - AnyRidge

Kwang Bum Park

Proceedings of the International Dental Materials Congress 2011, 2011.5, 39-45 (7 pages)

01. Summary

By adopting taper design, uniform core diameter with different depth of knife-threads and 5 degree of Morse taper, a new implant system named AnyRidge was developed with which we can make better initial stability, faster integration and more stable peri-implant bone responses. It is more interactive implant system ever, because an implantologist needs to choose different protocol of drilling according to patient's bone density, rather following a predetermined drilling sequence.

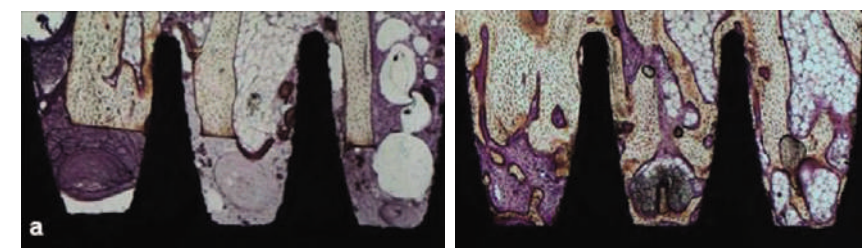
02. Introduction & Methods

For the last 20 years, there were tremendous developments and improvements in implant dentistry. Comparing with the first generation of intraosseous dental implant system, everything became faster, stronger and easier. And with the development of bone grafting materials and techniques, more and more people became possible to enjoy the benefit of dental implants. Dental implant design also has had many phases of change, especially on surface treatment technique to improve the speed of osseointegration and connection to minimize the chance of screw loosening and biologic width. However, there are still many controversies about the ideal design of dental implant.

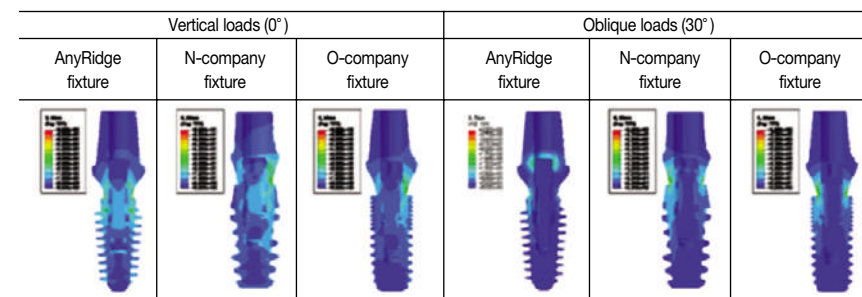
Generally speaking, the taperness of a fixture, the thread design, and the crestal module (neck of implant) play a critical role in minimizing stresses to bone and can decide the amount of initial stability. Tapered design produces more compressive forces but less shear forces than a cylindrical implant. Cutting edges at the apex was also considered as an important part to get better stability through self tapping. Making a definite core which has minimum diameter but enough strength with tapered design and putting a different depth of threads which can be applied according to the bone density to make same amount of initial stability can make a better implant by combining the taper design and thread with deep knife. Also, the biologic width which is made by the connection between a fixture and an abutment is also important for the maintenance of peri-implant crestal bone.

03. Results

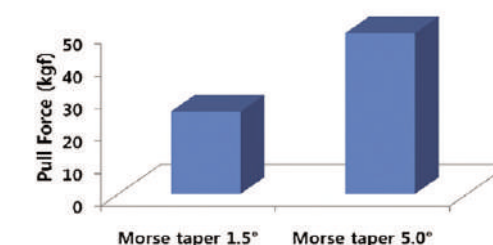
Among different types of internal connection, 11 degree Morse taper is the most popular. But with our test results, 5 degree Morse taper showed much tighter connection resulting complete hermetic sealing between an abutment and a fixture. On the pull-put test, the required force to separate the abutment from the AnyRidge fixture was almost double than 1.5 degree Morse taper connection system with friction-fit design. Also a screw loosening complication disappeared in most cases. With this advantage, we can reduce the diameter of abutment screw and helps to make fixture body stronger.



• Fig. 1. Histological sections of implants with the deeper thread at 0 day (a) and 4 weeks (b) after implantation in rabbit femurs.



• Fig. 2. Von Mises Stress contours (Cortical bone thickness : 0.8mm/ Cancellous bone level : D4)



• Fig. 3. The result of pull-out test of fixtures with Morse taper 1.5°(B-company fixture) and Morse taper 5° (AnyRidge fixture).

26.

Alveolar Ridge Reconstruction with Titanium Meshes and Simultaneous Implant Placement : A Retrospective, Multicenter Clinical Study

Raquel Zita Gomes, Andres Paraud Freixas, Chang-Hun Han, Sohueil Bechara, Isaac Tawil

BioMed Research International Volume 2016 (2016), Article ID 5126838, 12 pages

01. Summary

The horizontal ridge reconstruction with titanium meshes placed simultaneously with dental implants achieved predictable satisfactory results. Prospective randomized controlled trials on a larger sample of patients are required to validate these positive outcomes.

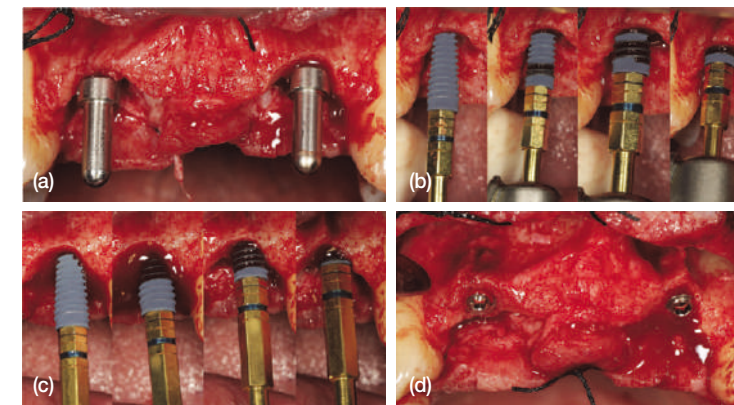
02. Introduction & Methods

Recently, titanium meshes that can be fixed directly on the implant have been introduced, but there is still a lack of clinical studies evaluating the efficiency and predictability of these membranes. Therefore, the purpose of the present retrospective, multicenter clinical study is to evaluate the horizontal bone gain, the percentage of implant survival, and the degree of complications in patients treated with titanium meshes positioned simultaneously with dental implants and fixed over them.

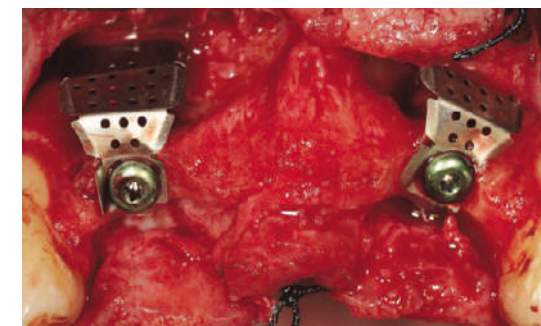
Twenty-five patients treated with 40 implants and simultaneous guided bone regeneration with titanium meshes (i-Gen Membrane) were selected for inclusion in the present retrospective multicenter study. Primary outcomes were horizontal bone gain and implant survival secondary outcomes were biological and prosthetic complications.

03. Results

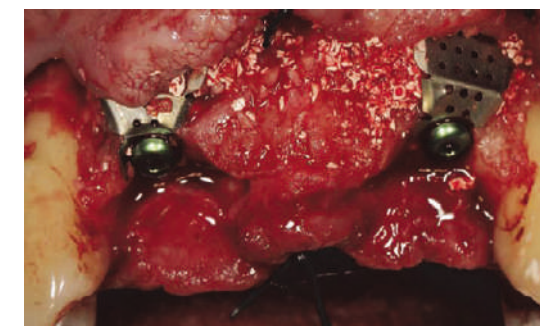
After the removal of titanium meshes, the CBCT evaluation revealed a mean horizontal bone gain of 3.67mm (± 0.89). The most frequent complications were mild postoperative edema (12/25 patients: 48%) and discomfort after surgery (10/25 patients: 40%); these complications were resolved within one week. Titanium mesh exposure occurred in 6 patients (6/25 : 24%): one of these suffered partial loss of the graft and another experienced complete graft loss and implant failure. An implant survival rate of 97.5% (implant-based) and a peri-implant marginal bone loss of 0.43mm (± 0.15) were recorded after 1 year.



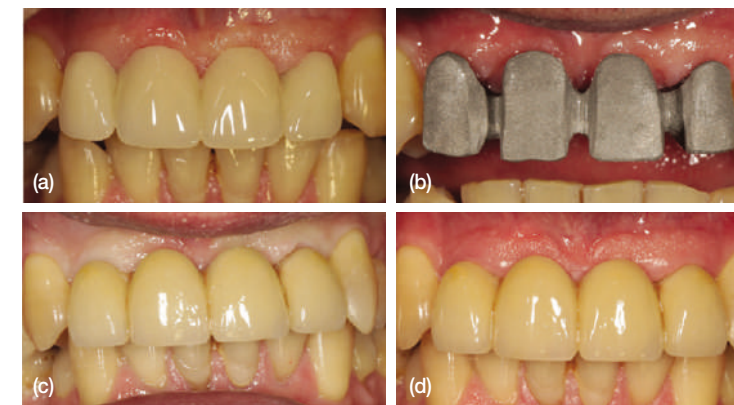
• Fig. 1. Preparation of the surgical sites and placement of the implants (AnyRidge, MegaGen, Gyeongbuk, Republic of Korea). (a) The implant sites have been prepared; (b) placement of the first implant in the position of the right lateral incisor; (c) placement of the second implant in the position of the left lateral incisor; (d) the implants in situ.



• Fig. 2. The titanium meshes are connected to the implants and screwed on with the aid of a connecting screw.



• Fig. 3. The titanium meshes are connected to the implants and screwed on with the aid of a connecting screw.



• Fig. 4. Prosthetic rehabilitations, (a) The provisional restoration in situ, two weeks after the first impressions; (b) three months later, the precision of final structure is tested clinically; (c) the application of the definitive metal-ceramic FPP; (d) the final FPP at the final control.

27.

Ridge Regeneration with a Titanium Membrane

Dinesh Vegad

Premium Practice Dentistry.

01. Summary

I-Gen membrane allows a good volume and quality of bone for placing implants without any compromises. Also, unlike other non-resorbable titanium-based membranes the I-Gen membrane allows for simultaneous implant placement and bone grafting. Moreover, the unique design allows this to be a single-stage procedure by using the healing abutments, or a two stage procedure with a cover screw.

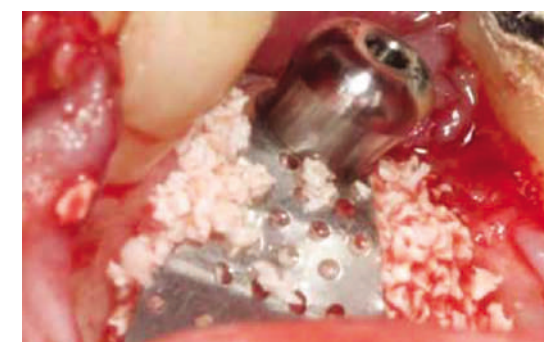02. Introduction & Methods

Pre-surgical planning, soft tissue management and aesthetic bone grafting are mandatory for an ideal outcome for dental implants. Good bone regeneration is the key to final success, 'tissue is the issue but bone sets the tone.' Unfortunately many resorbable membranes collapse too easily to be able to achieve good 3D bone regeneration, while traditional titanium membranes require a complicated fixing procedure and removal is also difficult and invasive. I-Gen (MegaGen) is a new flexible membrane which is easy to place and fix and create 3D bone shape and can be removed in two minutes!

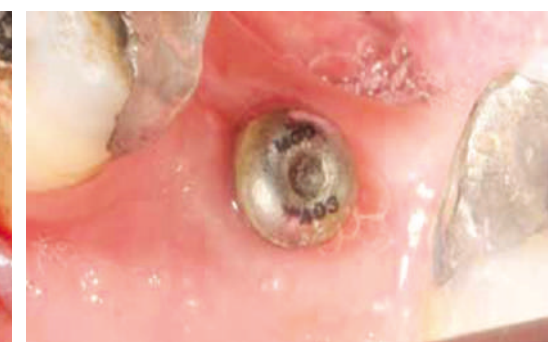The patient's alveolar ridge height was adequate while his tooth being extracted since two years ago. The implant was 5,00mm x 11,5mm (AnyRidge, MegaGen, Gyeongbuk, Korea). The design of this implant allowed a regular core diameter of 3,3mm with wide threads. The implant is also narrower at the two uppermost thread aspects and so avoids any pressure on cortical bone here. Primary stability was over 50Ncm. A flat abutment (3,5 x 1mm) was screwed into the implant. The I-Gen membrane (Type A wide) is wide and suitable for molar region. The I-Gen membrane can then be manually shaped to adapt well over the buccal defect.

03. Results

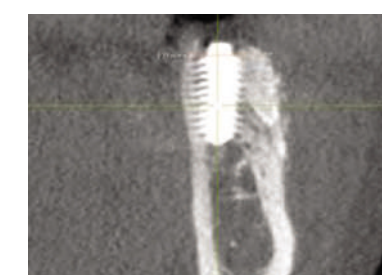Patient reported no swelling or pain and the I-Gen remained unexposed until five months later when, for study purposes, a flap was raised, the healing abutment removed and the I-Gen membrane was simple 'picked up' with tweezers. There was no binding of the I-Gen membrane to the newly formed, very hard, shiny cortical bone, well in excess of 4mm width. The bone was very hard and the buccal defect was completely filled. The soft tissue looked very healthy and with good bone support this implant has a very good long-term prognosis, provided restoration follows normal good design and occlusal considerations, a must for any implant.



• Fig. 1, Cerabone and I-Gen membrane in place



• Fig. 2, Excellent healing around abutment



• Fig. 3, Evidence of new good buccal bone formation

28.

In Vitro and In Vivo Osteoinductive and Osteoconductive Properties of a Synthetic Bone Substitute

Enrico Conserva, Federico Foschi, Ranieri Cancedda, Maddalena Mastrogiacomo

Oral and Craniofacial Tissue Engineering 2011;1:244-251.

01. Summary

The analyzed bone substitute of synthetic origin presented osteoinductive properties that may exert a differentiative stimulus upon osteoprogenitor cells. The tested material allowed cellular adhesion of osteoblastlike cells and, following tissue construct implantation in vivo, supported the formation of new bone.

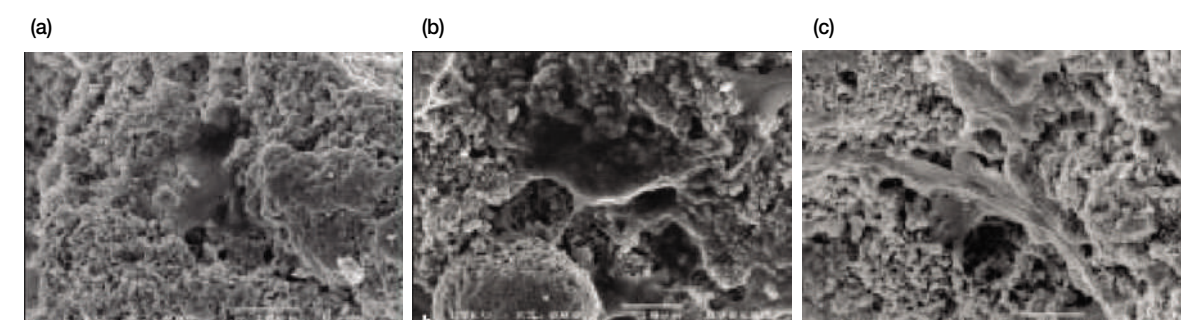
02. Introduction & Methods

The present study tested a recently introduced bone substitute material (BSM) with a novel structure to determine its osteoinductive and osteoconductive properties in vitro and in vivo. The specific aims were to determine the microstructure of the as-manufactured BSM, as analyzed with scanning electron microscopy, and to characterize different cellular interactions.

Human bone marrow stromal cells were cultured in the presence BSM. In vitro, attachment of osteoblastlike cells (SAOS-2) to the BSM was observed with the scanning electron microscope. The expression of genes related to osteogenic differentiation (alkaline phosphatase, bone sialoprotein, type I collagen, and osteocalcin) was determined by reverse-transcriptase polymerase chain reaction. In vivo, bone formation was examined with a murine model of ectopic bone formation through histology and computed tomographic scanning by using tissue-engineered constructs with the BSM and ovine bone marrow stromal cells.

03. Results

Early cellular attachment could be detected as early as 6 hours. Cellular morphology developed in the following 66 hours toward a starlike appearance. Human bone marrow stromal cells cultured in the presence of the BSM showed no reduction in their viability. Osteocalcin was up-regulated during cell culturing, demonstrating an osteoinductive effect on BSM. Histologic and computed tomographic analyses showed the formation of new bone surrounding BSM particles, and a vascular meshwork was observed in the porosity of the particles.



• **Fig. 1.** Microphotographs (magnification x 2,000) showing early adhesion after (a) 6, (b) 24, (c) 72 hours of osteoblastlike cells (ASOS-2) onto synthetic β -TCP/HA composite bone substitute. Cellular adhesion was already evident at 6 hours. Subsequently, the cellular morphology improved, with a starlike spreading morphology developing after 72 hours, as is typical mature osteoblastic cells

29.

Synchrotron X-Ray Bioimaging of Bone Regeneration by Artificial Bone Substitute of MegaGen Synthetic Bone and Hyaluronate Hydrogels

Junseok Yeom , Soeun Chang, Jung Kyu Park, Jung Ho Je, Dong Jun Yang, Seok kyu Choi, Hong-In Shin, Seung-Jae Lee, Jin-Hyung Shim, Dong-Woo Cho, Sei Kwang Hahn

Tissue Eng. Part C Methods, 2010 Oct;16(5):1059-68. doi: 10.1089/ten.TEC.2009.0759.

01. Summary

A clinically feasible artificial bone substitute consisted with MGSB and HA hydrogels was successfully developed for bone tissue engineering applications. Among artificial bone substitutes tested in this work, MGSB=HA-CYS hydrogels implanted in the calvarial critical-sized bone defects of New Zealand white rabbits resulted in the most effective bone regeneration.

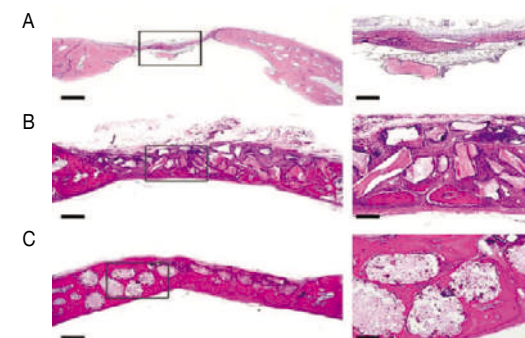
02. Introduction & Methods

Bone is a micro composite of hydroxyapatite crystallites and collagen-rich organic materials. There have been worldwide research efforts for bone tissue engineering. Various artificial bone substitutes have been designed and developed for rapid and efficient bone regeneration in clinical applications. A novel artificial bone substitute composed of MegaGen Synthetic Bone (MGSB) and HA hydrogels was developed for bone tissue engineering applications.

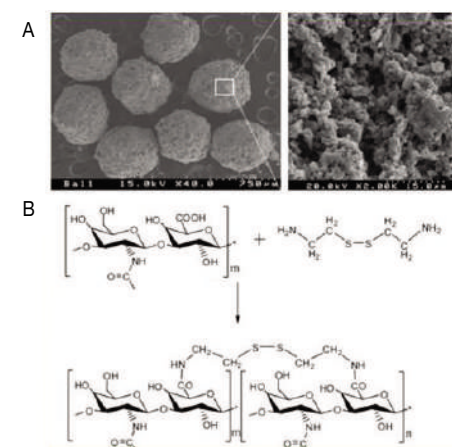
ABCP of MGSB was prepared by the chemical precipitation method using calcium nitrate tetrahydrate [Ca(NO3)2 ·4H2O] and ammonium phosphate dibasic [(NH4)2HPO4]. HA-ADH with approximately 70 mol% of ADH content was prepared. HA was dissolved in 0.2N sodium hydroxide (pH 13). After complete dissolution, DVS was added to the HA solution for the crosslinking reaction with hydroxyl groups of HA. HA was dissolved in PBS (0.01 M, pH 7.4) and CYS was added to the HA solution. The amount of CYS was 20 mol% of HA repeating units. EDC and HOBt, which activate the carboxyl groups of HA, were dissolved in PBS and added to the mixed solution of HA and CYS for HA-CYS hydrogel preparation. New Zealand white male rabbits weighing about 4 kg were anesthetized. The percentage of new bone formation was presented as the ratio of new bone area versus total defect area. In addition, the percentage of bio absorbed MGSB was presented as the ratio of MGSB area in 8 weeks versus that with a negligible biodegradation in 2 weeks.

03. Results

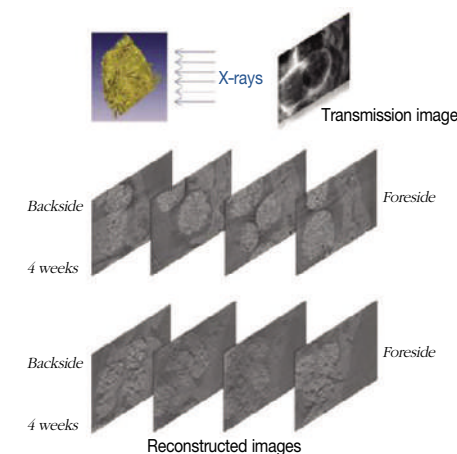
The bone regeneration by MGSB=HA-CYS hydrogels was as high as 43% and occupied 71% of the bone defect area with MGSB in the form of a calvarial bone plate. MGSB was biodegraded, bioabsorbed, and replaced gradually by newly formed bones, with increasing bone regeneration as observed in 8 weeks. Further, synchrotron X-ray imaging clearly confirmed the effective bone regeneration by MGSB=HA-CYS hydrogels, showing 3D micron-scale morphologies of regenerated bones being interconnected with MGSB. The sequential nondestructive synchrotron Xray tomographic analysis of void volume after bone regeneration also confirmed the effective bone regeneration by MGSB=HA-CYS hydrogels.



• Fig. 1. Photomicrographs of the calvarial critical-sized bone defects in New Zealand white rabbits after bone regeneration for 4 weeks: (A) control, (B) Bio-OSS, and (C) MGSB. Scale bars: left, 1000 mm; right, 200 mm.



• Fig. 2. Artificial bone substitute of MGSB and HA-CYS hydrogels. (A) Scanning electron microscopic image of a biphasic calcium phosphate of MGSB. (B) Schematic representation for the preparation of HA-CYS hydrogels.



• Fig. 3. Sequential synchrotron X-ray tomographic images of regenerated bones by MGSB= HA-CYS hydrogels in the calvarial critical-sized bone defects of New Zealand white rabbits after 4 and 8 weeks.

30.

Safety and effectiveness of maxillary early loaded titanium implants with a novel nanostructured calcium-incorporated surface (Xpeed) : 1-year results from a pilot multicenter randomized controlled trial

Marco Esposito, Maria Gabriella Grusovin, Gerardo Pellegrino, Elisa Soardi, Pietro Felice

Eur. J. Oral Implantol. 2012;5(3)

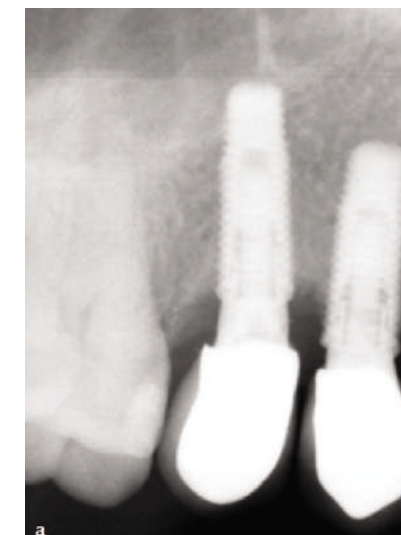01. Summary

Nanostructured calcium-incorporated titanium implants seem to be at least as effective and safe as conventional titanium implants.

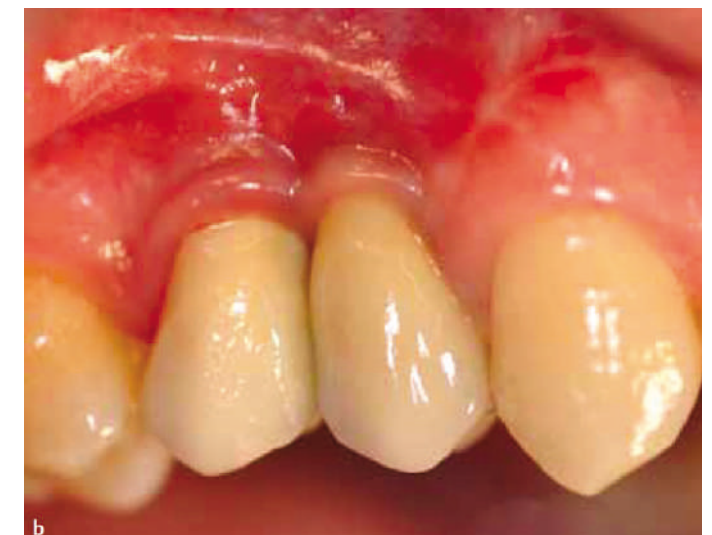02. Introduction & Methods

Among the newly developed implant surfaces, there is a nanostructured calcium-incorporated surface on titanium implants, which have been shown in an animal study to significantly improve the overall bone-to-implant contact and removal torque after 6 weeks over control titanium implants in rabbits.

Sixty patients were randomized to receive either 1 to 6 calcium-incorporated or control titanium implants in the maxilla according to a parallel group design at 2 different centers. Implants were submerged and exposed at 3 different endpoints in equal groups of 20 patients each at 12, 10 and 8 weeks, respectively. Within 2 weeks, implants were functionally loaded with provisional or definitive prostheses. Outcome measures were prosthesis failures, implant failures, any complications and peri-implant marginal bone level changes.



• Fig. 1. One-year periapical radiograph



• Fig. 2. One-year periapical radiograph

03. Results

Thirty patients received 45 calcium-incorporated implants and 30 patients received 42 control titanium implants. One year after loading, no drop-outs and no prosthesis or implant failures occurred. There were no statistically significant differences between groups for complications ($P = 0.61$; difference in proportions = -0.27 ; 95% CI -0.71 to 0.18) and mean marginal bone level changes ($P = 0.64$; mean difference -0.04 mm; 95% CI -0.22 to 0.13).

Effects of calcium ion incorporation on bone healing of Ti6Al4V alloy implants in rabbit tibiae.

Jin-Woo Park, Kwang-Bum Park, Jo-Young Suh
Biomaterials 28, 2007: 3306-3313

01. Summary

Ca-incorporated Ti oxide layer (CaTiO₃), produced by hydrothermal treatment using a mixed solution of NaOH and CaO, may be an effective tool for the improvement of the biocompatibility of Ti6Al4V implants.

02. Introduction & Methods

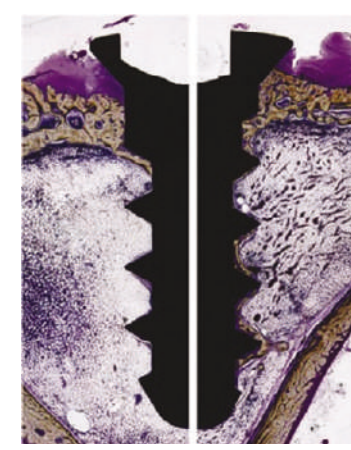
Titanium (Ti) and Ti6Al4V (Ti64) alloy have been used as endosseous implant materials in dentistry and orthopedics because of their good mechanical properties and biocompatibility.

The biocompatibility of Ca-incorporated Ti6Al4V alloy implants produced by hydrothermal treatment for future biomedical use. For this purpose, the surface characteristics and cell viability of Ca-incorporated Ti6Al4V alloy were investigated and its osteoconductivity was evaluated by removal torque testing and histomorphometric analysis after 6 weeks of implantation in rabbit tibiae.


Two different sample shapes, made from commercial Ti6Al4V(Ti64) plate with a thickness of 1 mm, were used to characterize the surface and evaluate cell viability. For the animal study, screw-type implants (n = 48) with an external diameter of 2.4mm and a length of 8 mm, made of commercial Ti64 alloy, with machined surfaces (machined implants) were purchase. This condition has been shown in a previous study to enhance bone healing around commercially pure Ti implants in rabbit tibiae. All implants were cleaned and sterilized in the manner described above.

03. Results

The biocompatibility of Ti6Al4V alloy can be improved by a Ca-incorporated oxide layer. Ca-incorporated Ti64 surfaces showed considerable apatite formation after they were soaked in HBSS. It has been suggested that the in vitro apatite-forming ability of Ti surfaces in simulated body fluid is consistent with the in vivo bone-bonding behavior of implants and that apatite formation is the decisive factor in osseointegration. Calcium ions in the CaTiO₃ layer may play a role in apatite formation because a greater number of phosphate ions can be adsorbed to the Ca-incorporated surface, resulting in the acceleration of calcium phosphate formation, as suggested by Hanawa et al.



• Fig. 1. Histological sections of machined (left) and Ca-incorporated (right) implants 6 weeks after implantation in rabbit tibiae



• Fig. 2. Scanning electron microscope images of Ti6Al4V samples soaked in HBSS for 4 weeks. (a) Ti6Al4V-0 and (b and c) Ti6Al4V-0.2 samples at magnifications of 1000 (a and b) and 30,000 (c). Ti6Al4V-0.2 samples show the formation of a thick apatite layer on their surfaces (b and c).

32.

Effects of a novel calcium titanate coating on the osseointegration of blasted endosseous implants in rabbit tibiae

Jo-Young Suh, Oh-Cheol Jeung, Byung-ju Choi, Jin-Woo Park

Clin. Oral Impl. Res. 18, 2007: 362-369

01. Objective

The purpose of this study was to investigate the effects of a nanostructured calcium coating on the surfaces of blasted Ti implants on peri-implant bone formation in the rabbit tibiae.

02. Material and methods

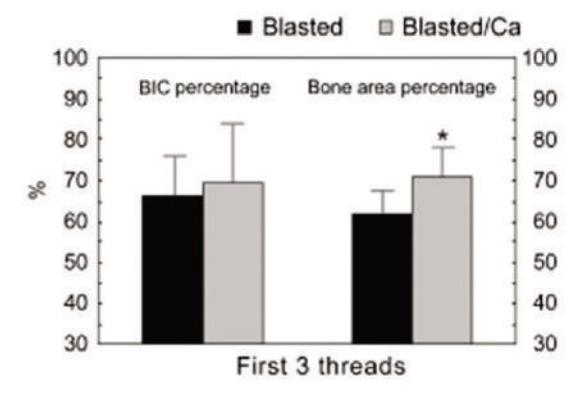
Threaded implants (3.75mm in diameter, 6mm in length) were roughened by hydroxyapatite (HA) blasting (control; blasted implants). The implants were then hydrothermally treated in a Ca-containing solution for 24 h to prepare Ca-incorporated Ti surfaces (experimental; blasted/Ca implants). Surface characterizations were performed by scanning electron microscopy and stylus profilometry before and after Ca coating. Forty-two implants (21 control and 21 experimental) were placed in the proximal tibiae of seven New Zealand White rabbits. Each rabbit received six implants. To evaluate the effects of the nanostructured Ca coating on the peri-implant bone-healing response, removal torque tests and histomorphometric analyses were performed 6 weeks after surgery.

03. Results

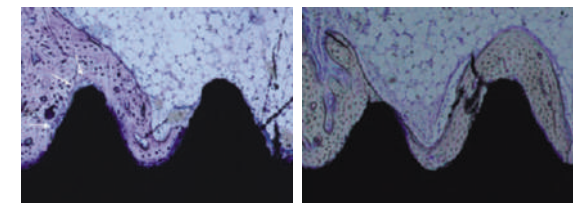
The Ca coating did not significantly change the surface properties produced by blasting at the micron level. Histologically, active bone apposition was observed in the blasted/Ca implants in the marrow space. Compared with the blasted implants, the blasted/ Ca implants showed significantly increased bone-to-implant contact over the total implant length ($P<0.01$) and greater mean removal torque values ($P<0.05$).

04. Discussion and conclusion

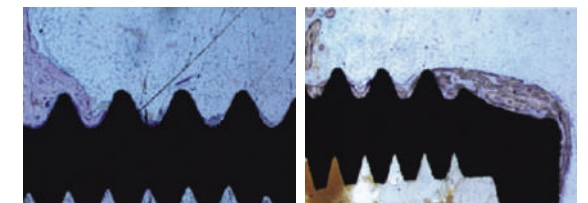
The nanostructured, Ca-incorporated surface significantly enhanced the peri-implant bone-healing response of HA-blasted Ti implants. It may be concluded that the use of nanostructured, Ca-coated surfaces may have synergic effects in enhancing osseointegration of blasted Ti implants due to their micron-scaled surface properties and biologically active surface chemistry.



• Fig. 1. There was a significant difference in bone area between the two groups ($nPo0.05$).



• Fig. 2. Histological sections of blasted (left) and blasted/Ca (right) implants at equivalent thread positions below the original cortex.



• Fig. 3. Histological sections of blasted (left) and blasted/Ca (right) implant 6 weeks after implantation in rabbit tibiae.

33.

Genetic Expression of SaOS2 cells grown on two different Implant Surfaces: An in vitro study

Enrico Conserva, Francesco Borghi and Ugo Consolo

J. Dent. Oro, Surg. 2(1): 127.

01. Summary

The incorporation of Calcium ions on a sand-blasted titanium surface did not modify the roughness but influenced positively cell proliferation and gene expression. The nanostructured Ca++ coating of Ti surfaces may be a potentially method to enhance osseointegration of micro roughened Ti implants by accelerating the adhesion, proliferation and differentiation of osteoblasts on their surfaces in the early bone healing phase.

02. Introduction & Methods

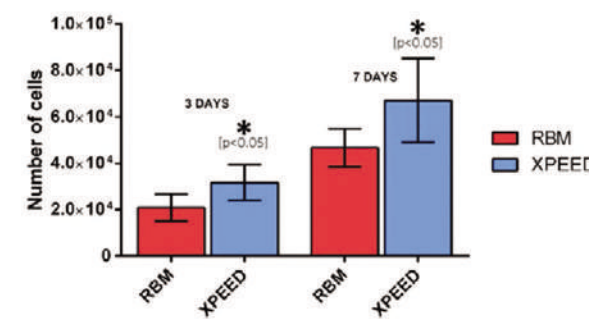
Since Titanium (Ti) and Ti alloys are not able to directly bond with bone, recently it has been suggested that a Calcium (Ca) ion-incorporated Ti oxide layer might enhance the osteointegration of Ti implants Ca-incorporation increased the osteoconductivity and the in vivo biochemical bone bonding of Ca-incorporated Ti implants has been demonstrated. Calcium titanate (CaTiO3) has been shown to promote osteoblast adhesion and proliferation and Ca composition, in the outer oxide layer, increased protein adsorption onto the Ti surfaces by ionic bonding, at a physiological pH, which subsequently affected cell adhesion.

The purpose of this study was to evaluate if Calcium incorporation via hydrothermal process may influence the biological cell response comparing two surfaces with similar roughness but different chemical composition.


Forty two commercial Titanium implants (AnyRidge, MegaGen Co. Ltd, Korea) were used in this study. The implants were processed with two different surface treatments: RBM (Resorbable Blast Media) and XPEED. Morphological and roughness analysis were performed respectively by SEM and Stereo SEM while chemistry was evaluated using EDX and XPS analyses. Gene expression was evaluated via qRT-PCR.

03. Results

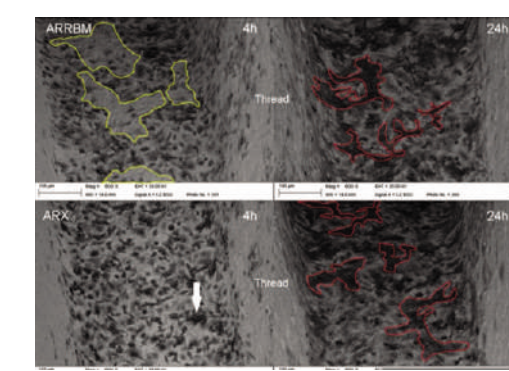
The nanometric Calcium layer on the XPEED surface did not influence the roughness and caused a nanotopography. SaOS2 proliferation at three and seven days increased on XPEED surface compared to RBM. PCR data of gene expression levels indicated that XPEED surface better affects the differentiation of SaOS2 cells.



• Fig. 1. This graph shows the statistically significant difference in proliferation, on RBM and XPEED surfaces, both at three and seven days.



• Fig. 2. SEM images that illustrate the morphology, adhesion and proliferation of cells grown on XPEED surface after 4 (A) and 24 (B) hours. [From left to right 1 K x, 5 K x, 7.5 K x].



• Fig. 3. SEM BSE (Back-Scattered Electrons) images that illustrate the difference in pattern of proliferation at four and 24 hours of SaOS2 osteoblast-like cells grown on both surfaces. The yellow areas, drawn for example, indicate parts of the surface not colonized. The white arrow indicates a group of SaOS2 cells after four hours with a typical globular morphology. After 24 hours the cell bodies flattened on the surface (see red areas drawn as example).

MEGAGEN
For Lifetime Smiles

MEGAGEN ARTICLES

POSTER :
IMPORTANT NUMBERS IN IMPLANT DENTISTRY
P.NO : 01-27

100 nm

The diameter of nanotube showing good implant stability.

Kwi-Dug Yun¹, Mong-Sook Vang¹, Hong-So Yang¹, Hyun-Pil Lim¹, Jung-Tae Koh¹, Sang-Won Park¹.¹. Department of prosthodontics, Chonnam national university, Gwang-ju, Republic of, Korea.

Objectives

To investigate the new nano-micro titanium implant surface on the implant stability and bone healing in beagle dogs.

Materials and Methods

48 screw-shaped implants (Megagen, Daegu, Korea), 4 mm in diameter and 8,5 mm in length, were used.

• Table 1. The implants were classification (n=12)

Group	surface	surface
M	M Machined surface	0.35±0.05
R	Resorbable Blasting Media(RBM) surface	1.95±0.10
MA	Nanotube on the machined surface	0.52±0.04
RA	Nanotube on the RBM surface	1.57±0.10

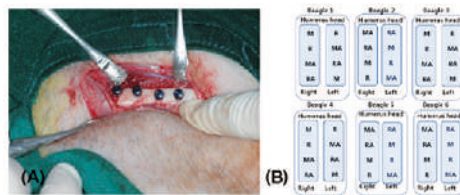
Anodic oxidation

Using constant voltage of 20 V for 10 min by a DC power supply (Fine Power F-3005; SG EMD, Anyang, Korea).

The electrolyte for anodizing consisted of 1M H₃PO₄ and 1.5 wt % HF solutions with a pH of 2-3. The nanotubes with 100~200nm in diameter and 500~600nm in length were developed.

Implant installation

The 6 beagle dogs (Beijing Marshall Biotechnology Co., Beijing, China), average 15kg weight and about 2 years old, were used. Each 4 implants are installed on left and right humerus of beagle dogs.



• Fig. 1.
(A) : Each 4 implants were installed on beagle' s humerus.
(B) : Schematic diagram of grouping on each beagle' s humerus.

Measurement

The insertion torque was measured during implant installation with ELCOMED (W&H, Burmoos GmbH, Austria).

The removal torque was measured at 4 and 12 weeks of implant insertion with torque measuring instrument (MGT12, ELECTROMATIC Equipment Co.Inc., Oakland, CA, USA).

The bone mineral density and bone volume were investigated using micro-CT (Skyscan1172, SKYSCAN, Antwerpen, Belgium). The results were statistically analyzed with two-way ANOVA.

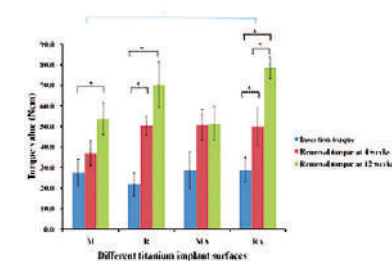
Results

Insertion torque

There were no difference in insertion torque values among differently surface treated titanium implants.

Removal torque

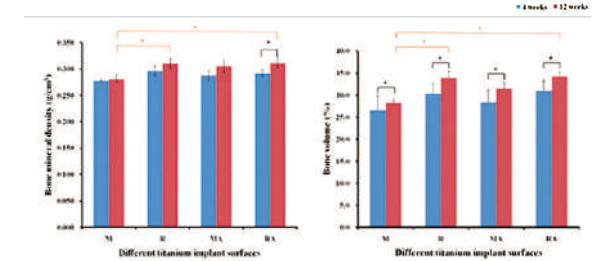
Comparing insertion torque value, removal torque values were significantly increased at 4 and 12 weeks. There were significant difference in removal torque value between 4 and 12 weeks only in the RA group. This suggest that the nanotubular implant surface has good early bone response.



• Fig. 2. Torque value on different titanium implant surfaces.
(* : significant at P<0.05, Statistically significance in relation to time was exhibited with black brackets, and statistical significance in relation to surface treatments was exhibited with a blue bracket).

Bone mineral density and bone volume

In RA group, Bone mineral density and bone volume were significantly increased as time passed by. R group and RA group showed significantly higher bone mineral density and bone volume than M Group at 4 and 12 weeks.



• Fig. 3. Bone mineral density (g/cm³) and Bone volume (%)
(* : significant at P<0.05, Statistically significance in relation to time was exhibited with black brackets, and statistical significance in relation to surface treatment at 12 weeks was exhibited with red brackets).

Conclusions

In this experiment, The RBM surface with nanotubular structures showed improved implant stability and better bone mineral density and bone volume. It suggested that this new nano-micro surface could improve the bone healing and be used in dental implant.

References

- 1 Bae IH, Yun KD, Kim HS, Jeong BC, Lim HP, Park SW, Lee KM, Lim YC, Lee KK, Yang Y, Koh JT. Anodic oxidized nanotubular titanium implants enhance bone morphogenetic protein-2 delivery. J Biomed Mater Res B Appl Biomater 2010;93:484-91.
- 2 Bjursten LM, Rasmusson L, Oh S, Smith GC, Brammer KS, Jin S. Titanium dioxide nanotubes enhance bone bonding in vivo. J Biomed Mater Res A 2010;92:1218-24.

3 x 3 x 121

3 protocols in 3 years on 121 implants

L. Dusi*, S.G. Marino*, N. Proserpio*

*DDS, Milano Bicocca University Dental School, Milan, Italy

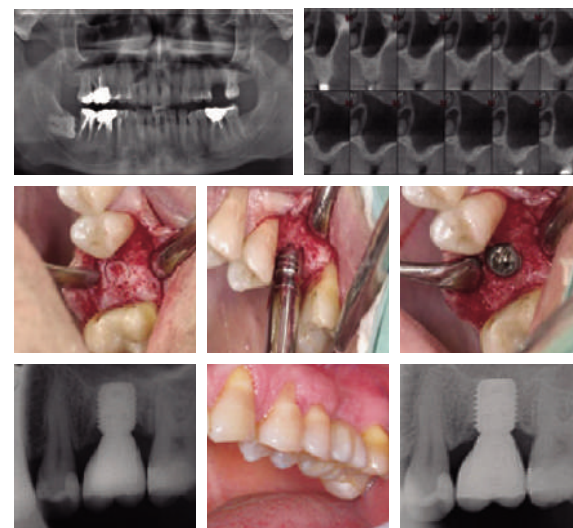
Objectives

To evaluate the survival rate of different kind of restoration supported by short implants during a 3-years follow up and compare this rate with the results of standard implants presents in literature.

Materials and Methods

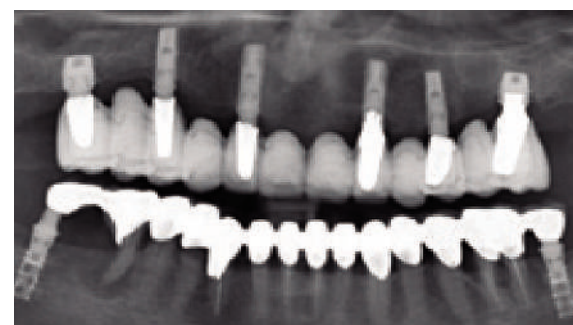
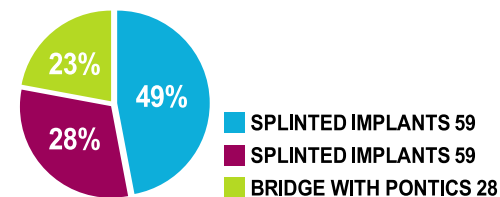
A prospective study were conducted on 121 short implants having lenght ranged between 5 and 7 mm and width from 6 to 8 mm. The implants were placed both in upper and lower arch.

Thirty-four implants were restored with single crowns, twenty-eight implants bridges with pontics, fifty-nine implants splinted implant bridges. The reasons that brought about the choice of a short implant were the impossibility to carry out advance surgery due to general health problems, patient refuse to the treatment plan, replacement of a previous implant failure.



2 YRS FOLLOW-UP

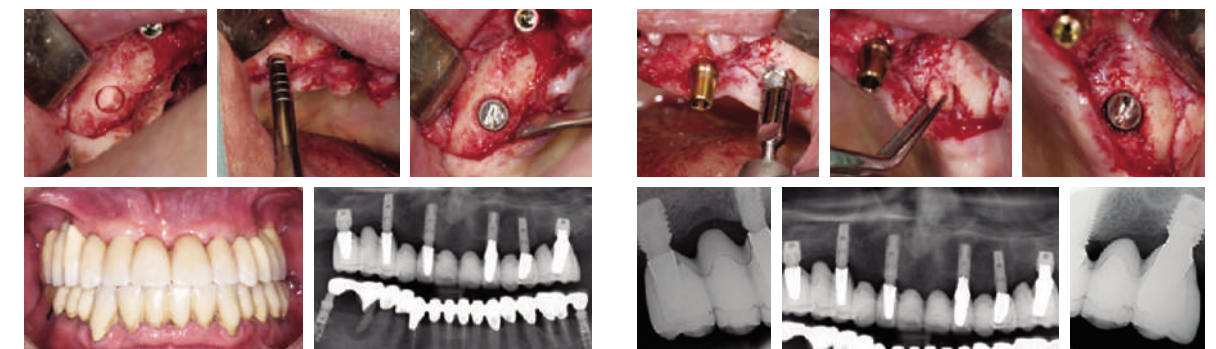
3 YRS FOLLOW-UP



Results

Six implants failures were recorded during the observational period. All the failures took place before second stage surgery and the most part of the problems occurred in the maxilla(5 failures). The cumulative survival rate was 95,5% (90,5% maxilla and 99,4% mandible). Our data are in concordance with other data presented in literature. No statistical differences among the different kinds of rehabilitation have been showed.

Conclusions



1 YR FOLLOW-UP

3 YRS FOLLOW-UP

References

- [1] Ten Bruggenkate CM, Asikainen P, Foitzik C, Krekeler G, Sutter F. Short (6-mm) nonsubmerged dental implants: results of a multicenter clinical trial of 1 to 7 years. *Int J Oral Maxillofac Implants* 1998; 13:791-798.
- [2] Hagi D, Deporter DA, Pilliar RM, Arenovich T. A targeted review of study outcomes with short (≤ 7 mm) endosseous dental implants placed in partially edentulous patients. *J Periodontol* 2004; 75:768-804.
- [3] Misch CE, Steigenga J, Barboza E, Dietsh F, Ciancila LJ, Kazor C. Short dental implants in posterior partial edentulism: a multi center retrospective 6-year case series study. *J Periodontol* 2006; 77:1340-1347.
- [4] Artzi Z, Parson A, Nemcovsky CE. Wide-diameter implant placement and internal sinus membrane elevation in the immediate postextraction phase: clinical and radiographic observations in 12 consecutive molar sites. *Int J Oral Maxillofac Implants* 2003; 18:242-9.
- [5] Degidi M, Piattelli A, Iezzi G, Carinci F. Wide-diameter implants: analysis of clinical outcome of 304 fixtures. *J*

39 kg vs 51 kg

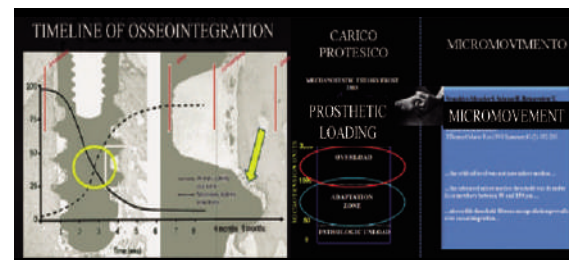
Loading effect on implants primary stability

S.G. Marino*, L. Dusi*, N. Proserpio*

*DDS, Milano Bicocca University Dental School, Milan, Italy


Objectives

To evaluate the necessary force to produce a 150 micron micromotion of dental implants placed in a biomechanical model of human bone (Sawbones). The results obtained have been compared with occlusal forces generated by the stomatognathic system.



Materials and Methods


Twelve internal connection implants (6 EZ Plus™ submerged and 6 ExFeel™ transmucosal) were inserted in a SAWBONES block. Implants have different threads pitch and depth and were inserted with a 50 Ncm torque and 30 rpm. Micromovement was measured with an extensometer linked to an INSTRON machine. Axial loading were applied to a maximum value of 900 N in 1 sec Δt. Extensometer allows to measure implant micromovement according to the increasing of applied force.



Results

For each implant placed threshold value above 150 micro was recorded. In particular for Ez Plus implants mean force value was -390,30 N (39 Kg), while for Ex Feel implants the mean value recorded was -511,5 N (51 Kg).

EZ PLUS	N	mm	EX FEEL	N	mm
A1	-372	0,1506	A3	-438	0,1547
A2	-355	0,1582	A4	-472	0,1562
B1	-396	0,1539	B3	-476	0,1522
B2	-358	0,1522	B4	-469	0,1579
C1	-428	0,1597	C3	-640	0,1552
C2	-433	0,1557	C4	-574	0,1536
MEDIA	-390,330	0,155	MEDIA	-511,50	0,154
SD	31,362	0,003	SD	71,24	0,002



Conclusions

The results obtained were similar to mean occlusal loading recorded in premolar area (40 and 50 Kg). Within the limits of this pilot study, the difference is probably due to different implant morphology: thread dimension and distance between threads. Nevertheless, in the immediate loading protocols, implants are splinted together and, probably, the previous showed values are not reached ensuring in this way long-term implants survival.

References

- [1] Raghavendra S, Wood MC, Taylor TD. Early wound healing around endosseous implants: a review of the literature. Int J Oral Maxillofac Implants 2005; 20:425-431.
- [2] Berglundh T, Abrahamsson L, Land NP, Lindhe J. De novo alveolar bone formation adjacent to endosseous implants. A model study in the dog. Clin Oral Impl Res 2003; 14:251-262.
- [3] Brunski JB. In vivo bone response to biomechanical loading at the bone/dental-implant interface. Adv Dent Res. 1999 Jun; 13:99-119.
- [4] Albrektsson T, Zarb G, Worthington P, Eriksson AR. The long-term efficacy of currently used dental implants: a review and proposed criteria of success. Int J Oral Maxillofac Implants. 1986 Summer; 1(1):11-25.
- [5] Szmukler-Moncler S, Salama H, Reingewirtz Y, Dubruille JH. Timing of loading and effect of micromotion on bone-dental implant interface: review of experimental literature. J Biomed Mater Res 1998 Summer; 43(2):192-203.

98.29%

Success Rate using MegaGen Rescue implants as an alternative choice to bone augmentation procedures, 1-4 years follow-up in 117 cases.

Siormpas K.*, Kontsiotou - Siormpa E.*, Efremidis I**.

*Private Dental Clinic, Larissa, Greece, siormpk@yahoo.gr, **Private Dental Clinic, Larissa, Greece, johnnyefr@gmail.com

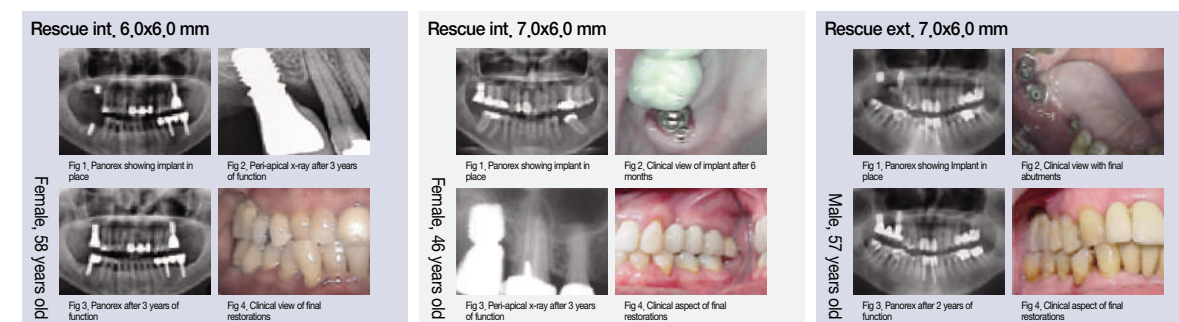
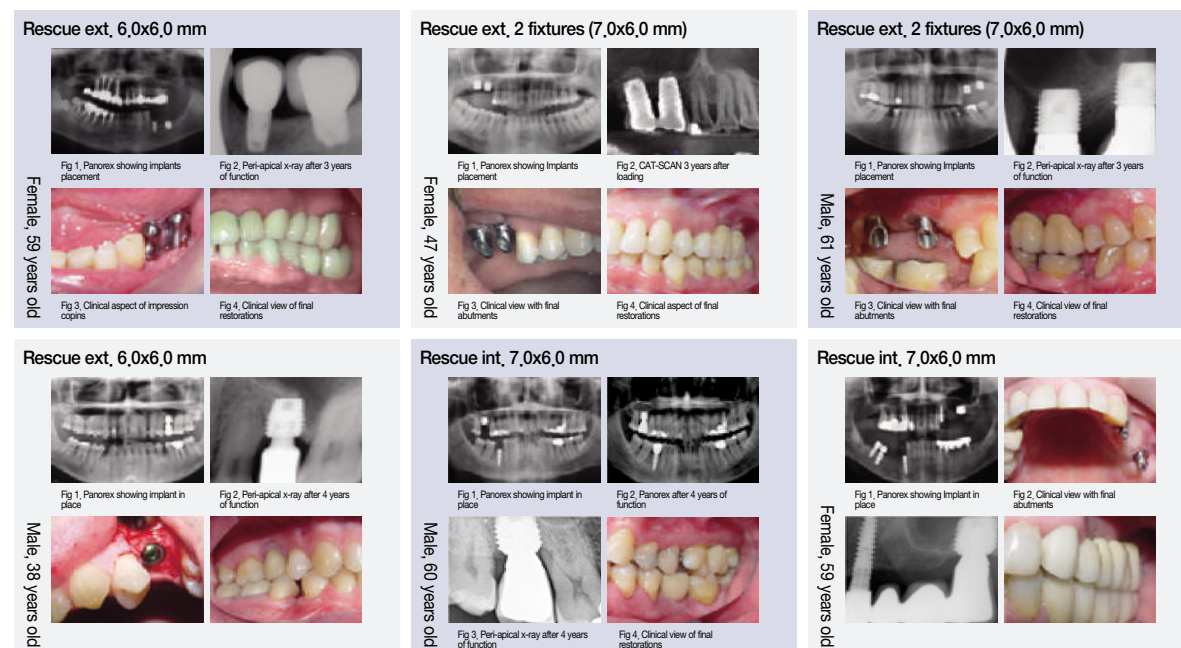
Introduction

Implant placement often becomes a very difficult task, due to lack of bone in height and width respectively. Regionally this occurs more at the posterior maxilla and mandible too (1). In order to achieve successful osseointegration, various techniques have been introduced. More specifically sinus elevation (open and close technique), vertical augmentation, distraction osteogenesis and lateral transposition of the inferior alveolar nerve. Nevertheless these techniques for various reasons, many times are not applicable or successful (2).

Short implants are defined the fixtures with equal or less of 8 mm (3). Recently the first results have been brought up to surface regarding the survival rates and the performance of them. This study presents 1-4 year results of a private clinic in Larissa, Greece.

Methods and Material

One hundred and seventeen fixtures (Rescue® MegaGen Co, Ltd, 377-2, Kyochon-Ri, Jain-Myun, Gyeongsan, Gyeongbuk, Korea) with a length between 5,0 to 8,0 mm, and a diameter of 6,0 to 8,0 were placed from 2007-2010 (4). Ninety nine patients (46 males, 53 females aged between 26-67 years of age with average age of 52,7 years were treated) participated in this private survey. From the 117 implants, ninety were placed in maxilla and the rest twenty seven were placed in mandible; 55 of these were restored with single crowns and 62 served as abutments of fixed partial dentures. Osseo integration period was standardized as 6 months for the upper arch and 3 for the lower arch. Regarding the restoration, all implants were restored using the same laboratory and technician. The superstructure design of choice was cemented porcelain fused to metal crown.



Results

From the ninety-two fixtures only two were not successfully integrated indicating a success rate of 98,29%. The later were replaced with other ones 5 months after the removal.

ARCH/sex	Male	Female	SUM
MAX	43	47	90
MAND	10	17	27
TOTAL	53	61	117

Conclusions

Short implants appear as an alternative to augmentation techniques. Their advantages are: decreased cost, decreased operation time, no sophisticated surgical interventions and less complications. Their increased diameter results in an improved emergence profile which is a typical issue with standard diameter fixtures when used at a molar location. Last the increased diameter outreaches the difference in length because of the increased osseointegration surface. Short implants are a valid treatment particularly in compromised cases where an augmentative technique cannot be used, in order to have a longer implant placed. This study indicated some results as trends for the value of short implants. More studies are necessary in order these trends to become solid.

References

- Renouard F, Nisand D. Impact of implant length and diameter on survival rates. Clin Oral Implants Res 2006;17 (Suppl 2: 35-51.)
- Feringo N, Laureti M, Fanali S. Inferior alveolar nerve transposition in conjunction with implant placement. Int J Oral Maxillofac Implants 2005; 20:610-620.
- Fugazzotto PA. Shorter implant in clinical practice rationale and treatment results. Int J Oral Maxillofac Implants 2008; 23:487-496.
- The Short Implant (from 5 to 7 mm in Length), Park KB, Roo KH, Jeong CW and Siormpas K, pp 267-291. Narae Publishing, INC.

5 years

5 years survival rates of 152 Short & Super-wide implant (Rescue, Megagen Co.) in atrophic maxillary posterior regions ; A retrospective study in 118 patients.

Min-Young Kim, Sung-Koog Jung, Seung-Yeup Lee

Daegu Mir dental hospital in Korea

Introduction

In the posterior maxilla, tooth loss is usually associated with alveolar bone resorption and sinus pneumatization, limiting the placement of implants without grafting procedures.

The use of short & super-wide implants have showed an acceptable clinical outcome in the treatment of the posterior of maxilla in many literatures. Of course, there are some considerable factors for success of implants which is bone quality, initial stability and practitioner's ability. In this study, after 6 years follow-up period after prosthetic loading, 118 patients (152 short and super wide implants (Rescue, Megagen co. Korea) were evaluated in maxillary posterior regions with insufficient bone height.

Materials & Methods

The retrospective study group consisted of the 118 consecutive patients (69 males, 49 females, mean age 61 years) treated with Rescue implant (Megagen co.,Korea) in 152 sites in Mir dental clinic, between 2004 and 2008 year. The patients were examined clinically and radiographic with intra-oral radiographs, panorama and computed tomograph if needed prior to surgery.

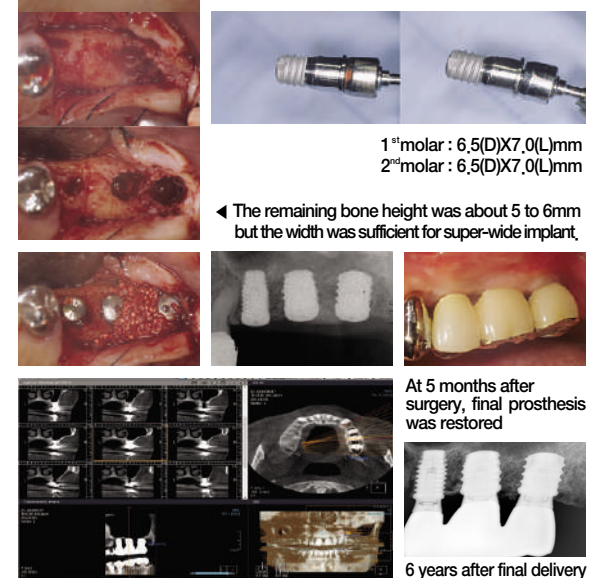
A total of 152 implants were placed; all implants in the maxilla and 24 immediate case and 128 healed ridge case. Implant lengths from 5 to 7mm and diameters from 6.0 to 8.0mm were used (Table 1). 63 implants underwent a GBR procedure. Crestal incisions were used and implant sites were drilled according to the guidelines given by the manufacturer and the implants were inserted with 50N torque. The patients were followed up with case records at fixture installation, at abutment connection, and at a follow-up visit 5 year after loading of the implants.

• Table 1.

	5mm	6mm	7mm
Ø6.0	·	2	20
Ø6.5	·	2	28
Ø7.0	2	18	59
Ø7.5	·	·	2
Ø8.0	·	4	14
total		152	

Case Report

Two 6.5mm diameter fixtures were placed at the left maxillary posterior area without sinus bone graft. The socket was filled chipped autogenous bone and allograft (Oragraft®, LifeNet Health, USA) and covered with e-PTFE membrane. (Gore tex®)



Results

161 of Rescue implants have passed the 5-year follow up. 9 implants failed in 8 patient before 1 year follow up, survival rate of 94.1% at 5-years (Table 2, 3)

• Table 2. (N : Numbers)

		N implants	N failure	Survival rate
Sex	Male	92	7	92.4%
	Female	60	2	96.6%
Length	5mm	2	·	100%
	6mm	27	2	92.6%
	7mm	123	7	94.3%
	2 nd premolar	5	·	100%
Regions	1 st molar	65	4	93.8%
	2 nd molar	82	5	93.9%

• Table 3.

failed implant for 5 years follow up periods caused by various reasons.

Pt.number	Position	Diameter	Length	GBR(Y/N)	Time of failure
1	26	Ø6	6mm	Y	9 months
2	17	Ø7	7mm	Y	6 months
3	17	Ø8	7mm	N	1 year
4	26	Ø7	7mm	Y	7 months
5	16	Ø7	7mm	Y	3 months
6	17	Ø7	6mm	Y	5 months
7	27	Ø6	7mm	N	4 months
8	26	Ø7	7mm	Y	9 months
9	17	Ø8	7mm	Y	6 months

Of the 152 implants placed in the maxillary posterior site, total 9 implants were removed which 3 of 9 were mobile at the time of secondary surgery and the rest were found sign of failure of osseointegration between bone and implant with 3~8 months after loading.

Discussion

Despite the high success rates of endosseous oral implants, restrictions have been advocated to their placement with regard to the bone available in height and volume. More recent studies which have used surgical preparation adapted to the bone density, textured-surfaced implants, and modified case selection have reported survival rates for short implants and for wide-diameter implants which were comparable with those obtained with long-implants and standard-diameter implants. In this study, after more than 5 years of loading, short & super wide implant (Rescue® Megagen co. Korea) shows a high success rate(94.1%) in patients with lowered maxillary posterior regions which may be needed vertical augmentation or sinus lift. As a results, it can be one of the solutions to solve the difficult situation. But continuous follow up will be needed to determine the long-term prognosis.

Reference

- Renouard F., Nisand D, Impact of implant length and diameter on survival rates, Clin Oral Implants Res, 2006 Oct; 17 Suppl 2:35-51
- Paulo Malo etc, Short implants placed one-stage in maxillae and mandibles : A retrospective clinical study with 1 to 9 years of follow- up, Clin Implant Dent Relat Res 2007 Mar;9(1):15-21

99.1%

Survival rates of AnyRidge implants : A retrospective and cumulative study

JunHong Park,

Dr. Hong Dental Clinic, KOREA

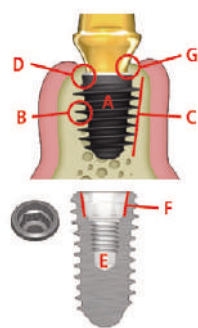
Objective

To evaluate the survival rates of new designed implant (AnyRidge threaded titanium implants with internal connection: MegaGen Implant Co. Ltd. Gyeongbuk, South Korea).

Material and Methods

For this study the majority of patients were treated at Daegu Mir Dental Hospital or at Dr. Hong's dental clinic between 2nd June, 2010 and 10th Jun, 2012 receiving AnyRidge Implants. The study was investigated cumulatively from 3 months after loading to 20 months after loading. Follow-up check was done twice a year. Implant treatment was as follows.

Anyridge Implant design and concepts



1. Implant design consideration

- A. Full textured surface (RBM surface) / B. Deep thread / C. Tapered body / D. Platform switching
- E. Internal connection / F. Cold welding connection (11° degree)

2. Surgical consideration

- G. Subcrestal implantation (1mm below)

Concepts

- Easy to achieve initial stability (deep thread, tapered body) Implant placement is possible while minimizing the elimination of existing bone (deep thread, tapered body)
- Minimize the elimination of crestal bone (narrow platform)
- No abutment loosening (friction connection)
- Soft tissue preservation. (narrow platform)
- Minimize early crestal bone loss (narrow platform, friction connection)

Surgical considerations

- A well-experienced surgeon in the dental clinical field was in charge of the surgery.
- Some patients continued smoking after surgery, despite doctor's caution.
- Patients with seriously bad general conditions were refused surgery.
- If tooth extraction was required, immediate placement was the treatment of choice where possible.
- Depending on the situation, 1 stage or 2 stage surgery was carried out.
- Depending on the situation, sinus graft with lateral or crestal approach was carried out.
- Depending on the aspect of the bone defect, bone augmentation was carried out as a simultaneous or staged approach.

Prosthetic considerations

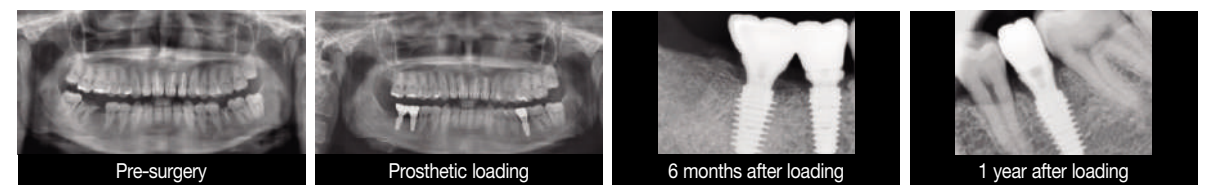
- Provisional restorations were placed 2 months post initial surgery in the mandible, 4 months post surgery in the maxilla.
- Final prosthetics were produced 1 month after PR delivery.
- Final impression was taken at the abutment level.
- All of final prosthetics was Cemented restoration.
- If the condition permitted, immediate loading was carried out.

Results

(Survival rates)	TOTAL(99.1%)	Healed Ridge(99.2%)	Immediate Placement(98.7%)	GBR(98.2%)	Sinus Graft(100%)
Failure	16	4	4	11	0
Total	1364	481	329	613	88

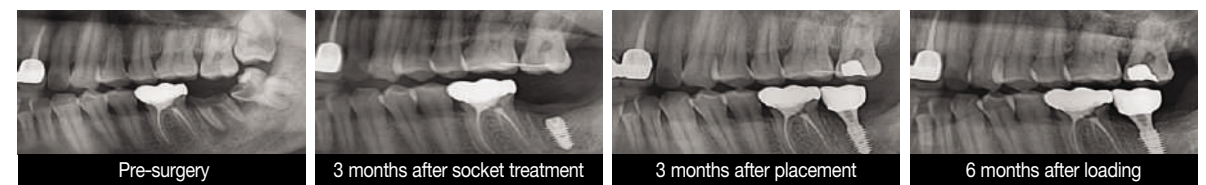
If the techniques of GBR + Sinus graft or Immediate placement are duplicated, there were decided each case, total number is different.

• Case 1, (Mrs. Yun) immediate implantation



New bone regeneration was observed up to top of fixture.

• Case 2, (Mr. Lee) implantation after socket treatment



Continuing new bone regeneration was observed after final prosthetic treatment up to abutment level.

Conclusion

The 2-year cumulative survival rates of 99.1% was achieved as a result of using the new implant AnyRidge design. The survival rates of most implant treatments which were carried out in this clinic was similar regardless of implant system.^{(1)Reference} Most of failure cases were carried out before prosthetics treatment. The reason of failure is considered new bone formation did not produced in case of the patients have severe bone defect.

To be successful in implant treatment:

- 1) you need to achieve initial stability when placing implant
 - 2) it is important to minimize crestal bone loss after prosthetics treatment.
- With AnyRidge initial fixation can easily be obtained and it is very easy to minimize additional bone graft surgery. In addition, AnyRidge invented based on the theory that it can minimize early crestal bone loss after prosthetics loading.^{(2-5)Reference} This was a short term clinical study and showed excellent results. Future long-term continuing research is needed.

References

- [1] Filiz Aydent, Ozgur Inan, Atilla Gokhan Ozyesil, Nilgun Ozlem Alptekin A 1- to 12 year clinical evaluation of 106 endosseous implants supporting fixed and removable prostheses. IJPRD Volume 27, Number 4, 2007 ; 358-367
- [2] Becker W, Goldstein M, Becker BE, Sennerby L. Minimally invasive flapless implant surgery: A prospective multicenter study. Clin Implant Dent Relat Res 2005;7(Suppl. 1):S21-S27.
- [3] Kim Y, Oh TJ, Misch CE, Wang HL. Occlusal considerations in implant therapy: Clinical guidelines with biomechanical rationale. Clin Oral Implants Res 2005;16:26-35.
- [4] Hemmann JS, Schoolfield JD, Schenk RK, Buser D, Cochran DL. Influence of the size of the microgap on crestal bone changes around titanium implants. A histometric evaluation of unloaded non-submerged implants in the canine mandible. J Periodontol 2001;72: 1372-1383.
- [5] Myshin HL, Wiens JP. Factors affecting soft tissue around dental implants: A review of the literature. J Prosthet Dent 2005;94:440-444.

5mm Δ CAL

Surgical therapy of peri-implantitis with decontamination using an air-polishing device and GBR with a bovine derived xenograft-a case report

I. Abas, C.E. Teulings and R. Junker

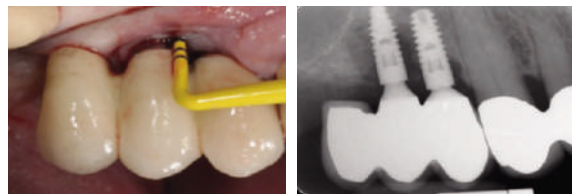Department of Implantology and Periodontology, Radboud University Nijmegen Medical Center, the Netherlands

Objective

The current objectives were (1) surgical implant surface decontamination with an air-polishing device and (2) bone reconstruction by means of GBR. The primary outcome measurement was Δ CAL between before and six months after surgery.

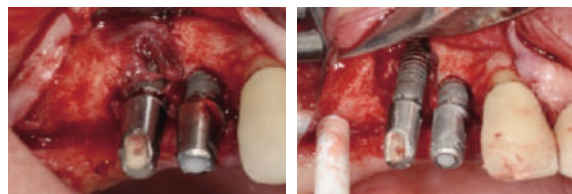
Materials and Methods

A 42-year old, non-smoking male presented with PPD up to 9 mm around 2 implants with a roughened surface (in situ for 2 years). 3 months after non-surgical peri-implant therapy patient was scheduled for surgical intervention.



Air-polishing

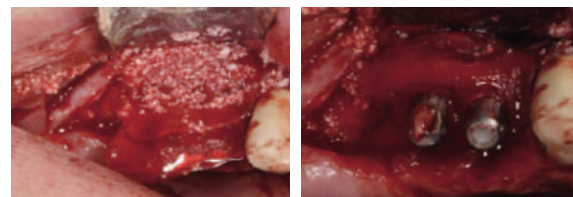
After removal of the FPD, a simplified papilla reservation flap was performed. Granulation tissue was removed with carbon curettes. The implant surface was decontaminated with an air-polishing device (EMS® Air-Flow Master) using amino acid glycine powder with a mean size of 63 μ m (PerioFlow®) for 2 times for 2 minutes.



Guided Bone Regeneration

For the deep, wide and primarily 2-wall intrabony defect, hard tissue reconstruction (i.e. bone reconstruction) was anticipated by means of GBR (bovine-bone derived xenograft (Bio-Oss®) and a bioabsorbable collagen membrane of porcine origin (Bio-Gide®).

Wound closure was achieved by modified internal, vertical mattress sutures with GoreTex® 5-0 suture material.

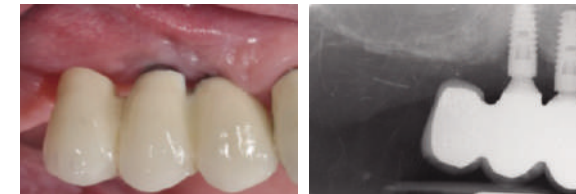


Pre-and post-operative regimen

Patient was given 3g of Amoxicillin preoperatively. Amoxicillin was continued for 1 week (3 times per day, 500mg). Further, the patient was instructed to rinse twice a day with a CHX-solution (0.2% / 15ml). Sutures were removed 2 weeks after surgery. Supragingival cleaning was performed at one week, two weeks, 1 month and every 1 month thereafter. For a period of 6 months peri-implant probing and subgingival peri-implant debridement was prohibited.

Result

At 6 months new peri-implant measurements and new radiographs were made. Δ CAL was up to 5 mm, Δ PPD was up to 5 mm, BOP was not found and recessions did not occur. The radiograph shows a significant amount of hard tissue.



Conclusion

Surgical decontamination of a peri-implantitis affected, roughened implant surface by means of an EMS® air-polishing device and PerioFlow® combined with GBR (Bio-Oss® / Bio-Gide®) for bone reconstruction was associated with favorable clinical results.

References

- Lang NP, Berglundh T. Periimplant diseases : where are we now? - Consensus of the seventh European Workshop on Periodontology. J Clin Periodontol 2011; 38 (Suppl. 11): 178-181.
- Schwarz F, Ferrari D, Popovski K, Hartig B, Becker J. Influence of Different Air-Abrasive Powders on Cell Viability at Biologically Contaminated Titanium Dental Implants Surfaces. J Biomed Mater Res Part B: Appl Biomater 2009 88B: 93-91.
- Schwarz F, Bieling K, Latz T, Nuesry E, Becker J. Healing of intrabony periimplantitis defects following application of a nanocrystalline hydroxyapatite (Ostim) or a bovine-derived xenograft (Bio-Oss) in combination with a collagen membrane (Bio-Gidet). A case series. J Clin Periodontol 2006; 33: 491-499.

5 years

A 5-years observational study of 50 Rescue implants

A. Maglione*, M. Cappello **, C. Allievi ***

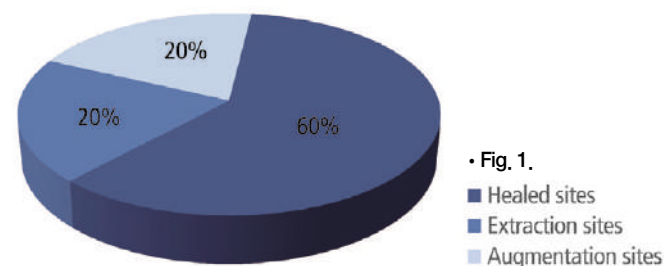
*DDS, Private Practice, Milan **DDS, Private Practice, Varese ***DDS, PhD , Private Practice, Milan

Objectives

This study investigates the survival rate and marginal bone resorption of 50 Rescue implants placed in the posterior atrophic maxilla after 5 years.

Materials and Methods

This study was performed on a total of 27 partially edentulous patients (11 men and 16 women) with an average age of 52 years. Before being included in this study, the medical history of each patient was collected. Those cases with severe systemic and oral diseases were excluded.

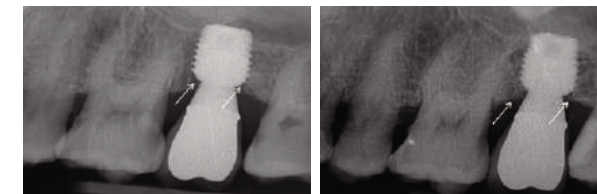


A total of 50 implants (delayed loading) were placed in the posterior maxillary sites. 60% of the implants were placed in healed sites and 20% of implants were placed in extraction sockets, 20% of the regions were augmented at the time of implant placement, (figure 1). All the restorations were cemented single crown or bridges. Once the planned prosthetic treatment was complete, instructions on hygiene and maintenance were provided. Radiographs were taken after implant placement, at loading (baseline), and 5 years after loading to calculate the bone loss over time. The mesial and distal first bone-to-implant contact levels were measured from the top of the implant-abutment connection to the highest level of bone-to-implant contact. Measurements were taken on the mesial and distal implant sites by means of a transparent millimeter ruler according to Rohlig et al (2009).

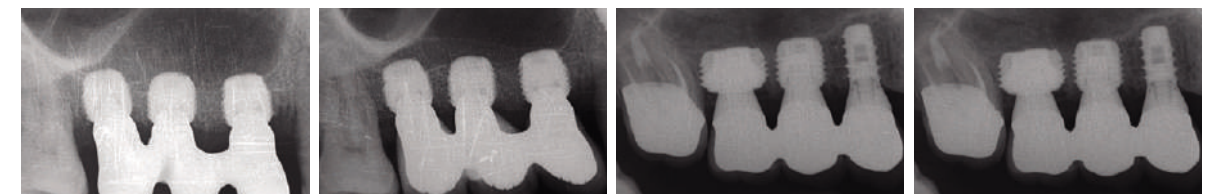Measurements were compared with those recorded at the baseline measurement. Descriptive statistics were calculated.

Results

Survival rates for the implants were 100% after 5 years. The average rates of mesial and distal marginal bone loss measured from the radiographs were -0,18 (sd 0,26) mm and -0,16 (sd 0,36) mm, respectively (figure 2,3).



• Fig. 2. Radiographs taken after the definitive restoration was completed and at the 5-year follow-up appointment. Notice the arrows indicating the marginal bone level (white).



• Fig. 3. Radiographs start and after 5 years.

Conclusions

This initial report demonstrates a survival rate of 100% after 5 years follow-up of the Rescue implant. This high survival rate is similar and higher than values reported in other studies and our values of marginal bone loss at implant sites were positive. Attention should be focused on oral hygiene maintenance to ensure peri-implant tissue health.

References

- [1] Ferrigno N, Laureti M, Fanali S, Grippaudo G. A long-term follow-up study of non-submerged ITI implants in the treatment of totally edentulous jaws. Part I: Ten-year life table analysis of a prospective multicenter study with 1286 implants. Clin Oral Implants Res. 2002;13(3):260-73.
- [2] Renouard F, Nisand D. Impact of implant length and diameter on survival rates. Clin Oral Implants Res. 2006;17(2):35-51.
- [3] Menchero-Cantalejo E, Barona-Dorado C, Cantero-Ávarez M, Fernández-Cáliz F, Martínez-González JM. Meta-analysis on the survival of short implants. Med Oral Patol Oral Cir Bucal. 2011;16(4):e546-51.
- [4] Gokcen-Rohlig B, Yaltirik M, Ozer S, Tuncer ED, Evlioglu G. Survival and Success of ITI Implants and Prostheses: Retrospective Study of Cases with 5-Year Follow-Up Eur J Dent. 2009;3(1):42-49.

3 methods

To compare the rhBMP-2 release kinetics from the implant surfaces according to different loading methods

Juri Ma¹, Hyeju Son¹, Jeongtae Koh¹, Jaesam Ban¹, Mongsook Vang¹, Hongso Yang¹, Hyunpil Lim¹, Gyejeong Oh¹, Kyunku Lee³, Seongsoo Kang², Kwangmin Lee⁴, Sangwon Park¹, Kwidug Yun^{1*}

1. Dental Science Research Institution, School of Dentistry, Chonnam National University, Gwangju, Republic of Korea
2. College of Veterinary Medicine, Chonnam National University, Gwangju, Republic of Korea
3. R&D Center for Ti and Special Alloys of GJTP, Gwangju, Republic of Korea
4. Department of Materials Science and Engineering, Research Institute for Functional surface Engineering, Chonnam National University, Gwangju, Republic of Korea

Introduction

The effective loading method of the rhBMP-2 on implant surface is essential for promoting bone formation and avoiding side effects. The aim of the study is to compare the rhBMP-2 release kinetics from the implant surfaces according to different loading methods.

Materials & Methods

Anodic oxidation

A total of 6 titanium RBM implants (Megagen, Daegu, Korea) which dimensions were 3.75 mm in diameter and 7 mm in length, were used. Anodic oxidation was performed at a constant voltage of 20 V for 60 min using a DC power supply (Fine Power F-3005; SG EMD, Anyang, Korea). The electrolyte for anodizing consisted of 1M H₂SO₄ and 1.0 wt % HF solutions with a pH of 2-3. A platinum plate (3 mm 4 mm 0.1 mm) was used as the anode, and the distance between the anode and cathode was 10 mm. All anodic oxidation processes were carried out at room temperature. After oxidation, the specimens were washed with water for 20 min and were dried for 24 h at 40°C in an oven.

Loading methods

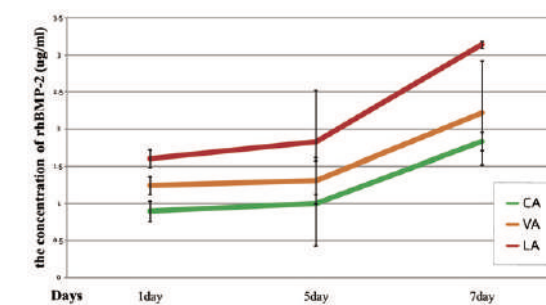
The rhBMP-2 loading method was divided into 3 groups ; coating and dry method, vacuum method, lyophilization method. Total 10ug rhBMP-2 was loaded into each titanium implant. 10 ug of the rhBMP-2 solution (1.5mg/mL) was dropped onto each Ti surface and dried in the air on coating and dry method, the same amount of rhBMP-2 was dropped onto each Ti surface, then applied in a vacuum glove box (Glove box , J-924A, JISICO, Seoul, Korea) at 0.1atm (76mmHg) for 10 minutes on vacuum method, and 10 ug of the rhBMP-2 solution (1.5mg/mL) was loaded onto each Ti surface, was lyophilized using freeze dryer (Clean vac 8, Hanil, Seoul, Korea) on lyophilization method.

Measurement of the amount of rhBMP-2

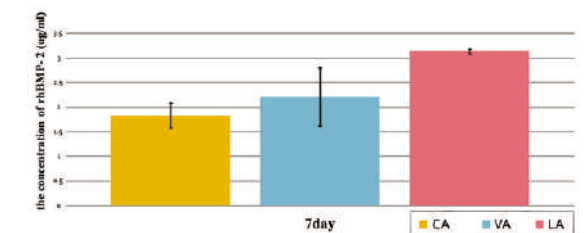
To measure the amount of rhBMP-2 released from Ti surfaces, the lyophilized specimens were placed in a phosphate-buffered saline (PBS) solution for 1, 5, and 7 days at 4_ with shaking gently. The amount of rhBMP-2 in the solution was measured using the rhBMP-2-specific enzyme-linked immunosorbent assay (ELISA) kit (R&D Systems, Minneapolis, USA) according to the manufacturer's instructions. The data were statistically analyzed with one-way ANOVA.

Results

1. A sustained release pattern was observed in each groups and lyophilization method showed highest loading amount (Fig 1).
2. At 5 days, the amount of the rhBMP-2 released from the coating method (CA) was 45% smaller than that from the RBM surface and 28% smaller than that from method (VA) (Fig 1).
3. The total amount of the rhBMP-2 released from the coating method (CA) was 58% of that from the lyophilization method (LA) and at total amount of the rhBMP-2 released from the vacuum method (VA) was 71% of that from the lyophilization method (LA) at 7 days (Fig 2).



• Figure 1. Release kinetics of the rhBMP-2 from the Ti surfaces



• Figure 2. Release kinetics of the rhBMP-2 at 7 days

Conclusion

The effective loading method of the rhBMP-2 on implant surface is essential to get the desired effect of the rhBMP-2 on osteoblastic differentiation and the rhBMP-2 should be released from the surfaces at appropriate timing and period. The results suggest that lyophilization method is effective to load rhBMP-2 on the nanotubular surface. In addition, functionalized nanotubular surface allowed sustained rhBMP-2 release according to time. These results suggest that the anodized Ti surface could be a useful sustaining carrier of rhBMP-2.

References

- 1 In-Ho B, Kwi-Dug Y, Hyun-Seung K, Byung-Chul J, Hyun-Pil L, Sang-Won P, Kwang-Min L, Young-Chai L, Kyung-Ku L, Yunzhi Y, Jeong-Tae K. Anodic oxidized nanotubular titanium implants enhance bone morphogenetic protein-2 Delivery. J Biomed Mater
- 2 Kim HS, Yang Y, Koh JT, Lee KK, Lee DJ, Lee KM, Park SW. Fabrication and characterization of functionally graded nano-micro porous titanium surface by anodizing. J Biomed Mater Res B: Appl Biomater 2009;88:427-435.

100%

Success rate using AnyRidge implants after 2 years of loading

Siormpas K ⁽¹⁾, Kotsiotou-Siormpa E ⁽¹⁾, Efremidis I ⁽¹⁾, Kotsakis G and Mitsias ME ⁽²⁾

1. Private Dental Clinic, Larissa, Greece, siormpk@yahoo.gr 2. Private practice, Athens, Greece, www.dental-center.eu

Introduction

During the immediate post-extraction period the buccal plate of a maxillary anterior dentition is most often very thin leading to significant dimensional alterations (Braut, et al. 2012, Nevins et al 2006). The intentional retention of roots, was the first approach that was introduced for the preservation of alveolar ridge dimensions (O' Neal et al 1978, Polyzois 1985). Ridge resorption can be categorized as a multi-factorial phenomenon that is partially attributed to the loss of blood supply, which is derived from the periodontal ligament (PDL) prior to tooth extraction (Araujo & Lindhe 2005). The intentional retention of the buccal aspect of the root ("Root membrane technique") with its periodontal apparatus has been proven to be efficient in maintaining a portion of the blood supply that derives from the PDL. Immediate implant placement with intentional preservation of the buccal portion of the root of a tooth may be an atraumatic approach leading to preservation of the blood supply of the buccal plate and consequent preservation of the dimensions of the alveolar ridge following immediate implant placement (Hurzel, et al. 2010). The implant rehabilitation of a tooth with hopeless prognosis in the esthetic zone without esthetic compromise remains elusive to date. The aim of the "Root membrane technique" is to evaluate the feasibility of this approach in a clinical practice setting and to report longitudinal data on survival rate of the respective implants placed.

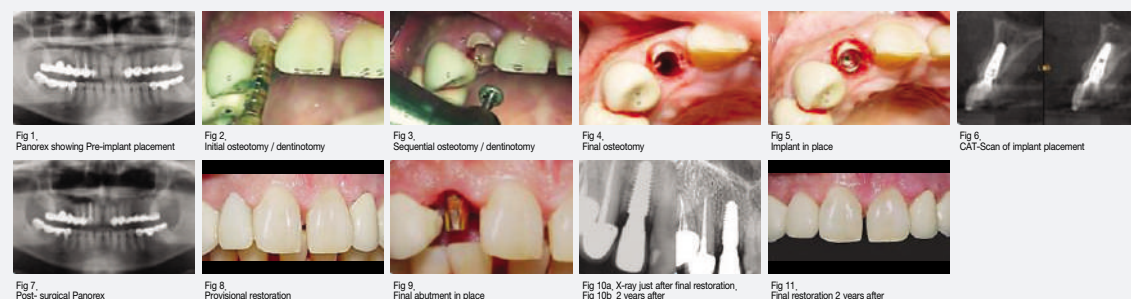
Materials and Methods

Twenty-two fixtures (AnyRidge[®] MegaGen Co, Ltd, 377-2, Kyochon-Ri, Jain- Myun, Gyeongsan, Gyeongbok, Korea) with a length between 10 to 13,0 mm, and a diameter of 3,5 to 4,5 mm were placed from 2011-2012 (4).

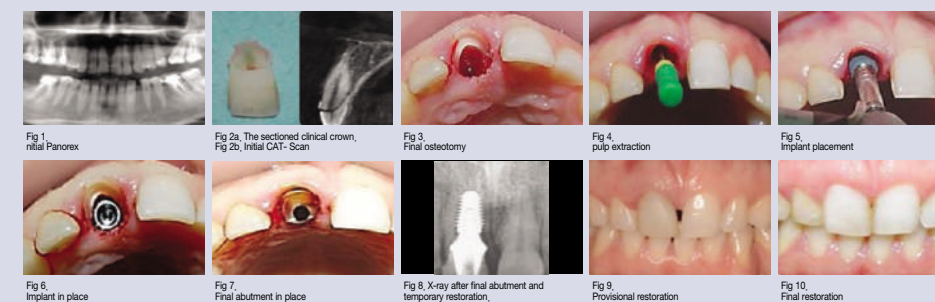
Twenty one patients (9 males and 12 females aged between 27-64 years of age with average age of 46, 2 years were treated) participated in this private survey. All implants were immediately loaded with a cement-retained acrylic interim restoration fabricated as per routine protocol of this clinic for immediate implant placement in the esthetic zone.

The final superstructure design of choice was cemented zirconium oxide-porcelain from the same laboratory and technician. The crown of the involved tooth was removed with a conventional chamber diamond bur under copious irrigation until the remaining tooth structure was leveled one millimeter above the osseous crest. The reason for not reducing it at the level, or even below the osseous crest was to maintain the dentogingival fibers intact to enhance soft tissue esthetics. The osteotomy sites were prepared by drilling through the long axis of the roots. This technique implements with gradual endoroot extraction (dentotomy - osteotomy) of the palatal aspect of the root following the drilling sequence suggested by the implant manufacturer.

• 1. Female, 50 years old



• 2. Female, 44 years old



Results

All twenty-two fixtures were successfully integrated indicating a success rate of 100%. CBCT evaluation indicated that there was no bone loss during this period of time regarding the alveolar ridge.

Conclusions

The "Root membrane technique" (immediate implants placement and loading in the aesthetic zone of the maxilla), has been proven to be a successful alternative method for the esthetics preservation of the tissues in this demanding area. More studies have to take place in order to establish this trend technique as a validated scientifically surgical procedure.

ARCH/sex	PATIENTS	ANYRIDGE IMPLANTS	SUCCESS RATE %
MALE	9	10	100
FEMALE	12	12	100
TOTAL	21	22	100

References

- [1] Araujo, M. G., & Lindhe, J. (2005) Dimensional ridge alterations following tooth extraction. An experimental study in the dog. J Clin Periodontol 32: 212-218.
- [2] Braut, V., Bomstein, M. M., Lauber, R. & Buser, D. (2012) Bone dimensions in the posterior mandible: A retrospective radiographic study using cone beam computed tomography. Part 1—analysis of dentate sites. Int J Periodontics Restorative Dent 32: 175-184.
- [3] Davarpanah, M. & Szmukler-Monder, S. (2009) Unconventional implant treatment: I. Implant placement in contact with ankylosed root fragments. A series of five case reports. Clin Oral Implants Res 20: 851-856.
- [4] Hurzel, M. B., Zuh, O., Schupbach, P., Rebele, S. F., Emmanouilidis, N. & Fickl, S. (2010) The socket-shield technique: A proof-of-principle report. J Clin Periodontol 37: 855-862.
- [5] Nevins, M., Camelo, M., De Paoli, S., Friedland, B., Schenk, R. K., Parma- Benfenati, S., Simion, M., Tinti, C. & Wagenberg, B. (2006) A study of the fate of the buccal wall of extraction sockets of teeth with prominent roots. International Journal of Periodontics and Restorative Dentistry 26, 19-29
- [6] O' Neal, R. B., Gound, T., Levin, M. P. & del Rio, C. E. (1978) Submergence of roots for alveolar bone preservation. I. Endodontically treated roots. Oral Surg Oral Med Oral Pathol 45: 803-810.
- [7] Polyzois, G. L. (1985) An update on the submerged-root concept. Evolution and current knowledge. Clin Prev Dent 7: 14-22.

3

Three-dimensional analysis for implant thread slope and angulation

H.S. JOO*, Y.H. Seo, M.S. Vang, H.S. Yang, S.W. Park, H.P. Lim, K.D. Yun, W.C. Shin

Department of Prosthodontics, School of Dentistry, Chonnam National University, Gwangju, Korea

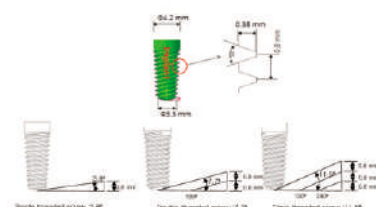
Background and Aim

The amount and form of stress transmitted to alveolar bone are changed according to the implant thread and its geometrical form. There are few studies about the stress distribution aspect with different implant thread slope and angulation, the number of thread, width of the thread pitch, diameter and length of fixture. The aim of this study was to find an inclination slope of the screw thread favorable for distributing the stress to alveolar bone by using three dimensional finite element analysis.

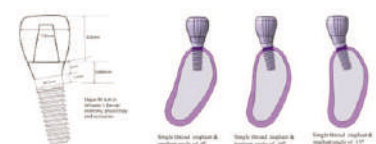Methods and Materials

In this study, the model of the implant has the 0.8 mm pitch, 0.38 mm spiral ridge and, 50° thread angle of a screw in the finite element model.

Three different types of implant thread slope models were used. Each type of implant thread slope had fixed pitch of 0.8mm and different inclination of the thread: single thread implant with 3.8° inclination, double thread implant with 7.7° inclination and triple thread with 11.5° inclination.



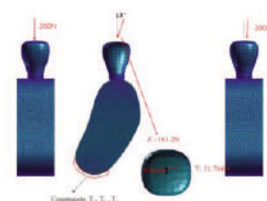
• Fig. 1. The diagram of the implant has different thread slope and the pitch in three types that is the single, double, triple threaded screw.



• Fig. 2. (Left) Design a dimension of restored prosthesis that cervical-occlusal is 8.5 mm and buccolingual is 7.5 mm according to Wheeler's dental anatomy, physiology and occlusion, (Right) Schematic drawing of the different implant angulation that is 0°, 10° and 15° in a bone.

For the analysis of implant angulation, we assumed that these three thread types installed on alveolar bone having 0°, 10° and 15° angulation respectively.

Therefore, totally 9 models were fabricated for three dimensional finite element analysis on restored prosthetic crown. 200 N vertical load or/and 15° tilting load were applied on center of the crowns. In only vertical loading group and vertical and tilted loading group, the stress distribution on implants and alveolar bone was analyzed respectively by using three dimensional finite element analysis.



• Fig. 3. The finite element model with meshing of 200 N vertical load and 15° tilting load applied on the crown center.

In requirement of the model, the jaw base should be completely fixed. And the difference of stress distribution is illustrated by 15 grades of colors which are consist from gray to red. Furthermore we observe the x, y, z axes of phase of stress to compare them with the general stress distribution state. We used CATIA V5 program to design procedure of finite elemental model. As a preprocessor and translator, MSC, PATRAN 2005 are used. The von-Mises stress and maximum principal stress are listed on table I, II.

Results

1. The von-Mises stress of implant and alveolar bone increased as the implant angulation increased.
2. The von-Mises stress and the maximum principal stress increased more when 15° tilting load were applied on alveolar bone compared with vertical loading.
3. As the number of thread was increased, the von-Mises stress and the max principal stress reduced due to increased distribution of the stress.
4. The amount of maximum principal stress on alveolar bone of triple thread implant in vertical loading or tilted loading had the smallest value compared with single and double thread implant.

Angulation	Type	Implant		Cortical bone		Cancellous bone	
		Vertical.	15° tilting	Vertical.	15° tilting	Vertical.	15° tilting
0°	Single Thread	44.3	181	32.6	127	19.7	72.7
	Double Thread	46.6	160	32.2	137	19.1	71.6
	Triple Thread	44.5	146	29.6	129	17.5	70.2
10°	Single Thread	73.9	218	51.8	152	28.3	84.3
	Double Thread	75.4	195	51.5	165	28.8	87.6
	Triple Thread	66.8	175	50.9	154	28.2	84.8
15°	Single Thread	88.8	237	65.0	164	35.2	91.6
	Double Thread	91.3	213	65.3	179	36.4	95.6
	Triple Thread	80.4	189	63.1	166	34.9	92.4

• Table 1.
Von-Mises stress of the different implant types and implant angulation with 200 N vertical load and 15° tilting load. (MPa)

Angulation	Type	Implant		Cortical bone		Cancellous bone	
		Vertical.	15° tilting	Vertical.	15° tilting	Vertical.	15° tilting
0°	Single Thread	25.8	217	13.5	121	13.3	56.9
	Double Thread	25.4	183	12.0	123	13.9	53.8
	Triple Thread	23.4	121	15.9	106	15.9	54.0
10°	Single Thread	38.7	232	20.6	163	20.6	70.8
	Double Thread	35.2	241	20.2	177	21.3	69.0
	Triple Thread	23.0	163	15.4	143	15.4	77.6
15°	Single Thread	45.0	331	24.3	184	24.3	78.0
	Double Thread	41.7	271	28.6	206	25.0	70.0
	Triple Thread	27.1	186	20.8	163	18.1	79.2

• Table 2.
Maximum principal stress of the different implant types and implant angulation with 200 N vertical load and 15° tilting load. (MPa)

Conclusions

From the results described above, the stress distribution of triple thread implant which has larger inclination is superior than that of single and double thread implant. Even in cases of tilted installation of implant more than 10°, the optimized the thread number and slope inclination can help prolong the longevity of implant because the maximum principal stress reduced as implant thread slope and the number of thread increased.

References

1. Branemark P-I: Osseointegration and its experimental background, J Prosthet Dent 1983;50:399-410.
2. Adell R, Lekholm U, Rockler B, Branemark PI: A 15 year study of osseointegrated implants in the treatment of the edentulous jaws. Int J Oral Surg 1981;6:387-416.
3. Skalak R: Biomechanical consideration in osseointegrated prosthesis, J Prosthet Dent 1983;49:843-848.
4. Holmes DC, Grigsby WR, Geol VK, Keller JC: Compression of stress transmission in the IMZ implant system with polyoxymethylene or titanium intramobile element/finite element stress analysis, Int J Oral Maxillofac Implant 1992;7:450-458.
5. Brunski JB: Biomaterial and biomechanics in dental implant design, Int J Oral Maxillofac Implants 1988;3:85-97.
6. Rangert B, Jemt T, Joemeus L: Forces and moments on Branemark implants, Int J Oral Maxillofac Implants 1989;4:241-247.
7. Holmgren EP, Seckinger RJ, Kilgren LM: Evaluating parameter of osseointegrated dental implant using finite element analysis a two-dimensional comparative study examining the effect of implant diameter, implant shape and load direction, J Oral Implantol 1998;14(2):80-88.

99.2 %

1 year survival rates of 378 AnyRidge implants with Xpeed surface ; A retrospective study in 156 partially edentulous patients.**Sung-Koog Jung, Yeon-Kang Jung, Seung-Yeup Lee, Kwang-Bum Park**

Daegu Mir dental hospital in Korea

Introduction

There are many factors to be considered for the successful implant therapy. Most of all, the surface treatment of implant has been being a main concern. Over the years, to increase the speed of osseointegration and promote the response between fixture and bone tissues, many kinds of surface treatments have been developed. HA, RBM and SLA are representative. The Xpeed surface treatment was applied to AnyRidge® Implant (MegaGen Co., Korea), which fast and strong osseointegration is possible with nano bone matrix layer due to Ca⁺ incorporation on the SLA surface and more safety come from double checking system.

This retrospective study investigates the survival rate of 378 AnyRidge® implant (MegaGen Co, Korea) with Xpeed® surface placed in the edentulous ridge in 156 patients after loading for minimum 6 months from June 2012 to April 2013.

Materials & Methods

The retrospective study group consisted of the 156 consecutive patients (68 males, 88 females, mean age 60.7 years) treated with AnyRidge® implant (MegaGen Co., Korea, Xpeed® surface) in Daegu Mir dental Hospital, between June 2012 and April 2013. In most cases, crestal incisions technique was used, and implant sites were drilled according to the guidelines given by the manufacturer. A total of 378 implants were placed; 208 implants in the maxilla and 170 in the mandible (94 immediate placement after extraction). Implant fixture diameter was from 3.5 to 8.0mm and from 7 to 15mm in length (Table 1).

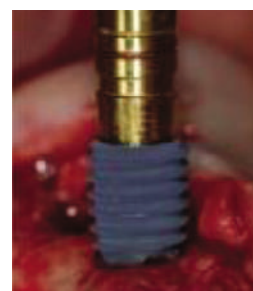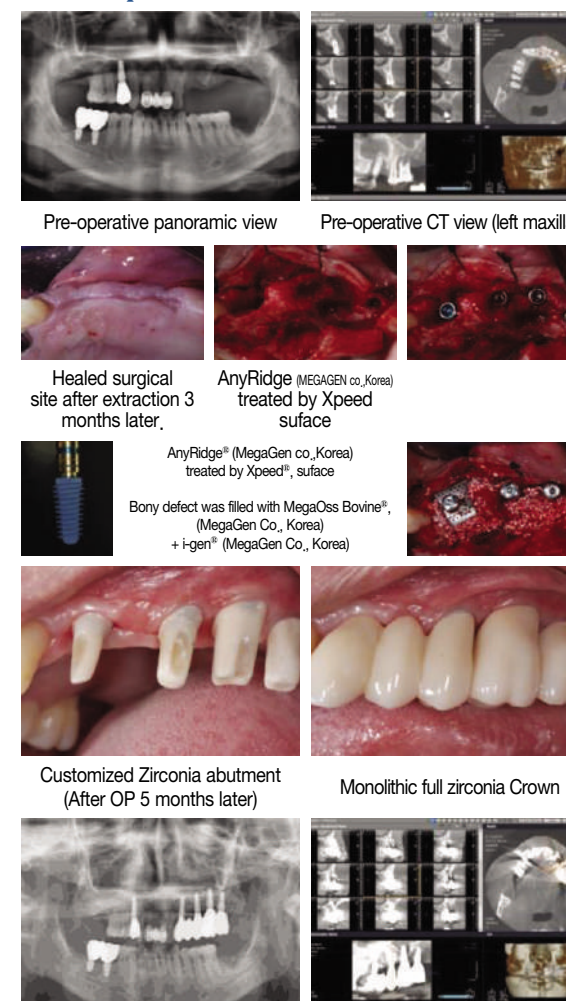
In 103 patient, 209 implants was placed with GBR procedures.

	Ø3.5	Ø4.0	Ø4.5	Ø5.0	Ø5.5	Ø6.0	Ø6.5	Ø7.0	Ø7.5	Ø8.0
7mm
8.5mm	2	17	8	16	.	14	3	1	1	.
10mm	11	55	35	11	.	17	6	2	.	.
11.5mm	20	36	22	6	1	7	7	3	2	.
13mm	23	24	23	2	.	.	2	.	.	.
15mm

• Table 1.



During the process of Xpeed®, treatment, the SLA surface is completely neutralized without any acid residue. The blue color of Xpeed® surface is the symbol of purity.

XPEED® surface**Case Report****Results**

378 AnyRidge® Implant (MegaGen Co., Korea) in 156 patients was placed and loaded after final restoration delivery for minimum 6 months. For less than 6 months, 1 implant in 1 patient was failed. A cumulative survival rate was 99.2% for AnyRidge® implant (MegaGen Co., Korea) with Xpeed® surface. Table 2. (The success and survival criteria used in this report are a modification of the success criteria suggested by Van Steenberghe) Of the 378 implants, 1 implant was extracted after loading less 6 months, 2 implants were mobile at time of the osseointegration period with 3~6 months after surgery. Table 3 is previous study that is AnyRidge® with super RBM surface result.

	N implants	N failure	Survival rate
Sum	378	3	99.2%

• Table 2.
AnyRidge® implant with Xpeed® surface (N : Numbers) : 2012~2013

		N implants	N failure	Survival rate
Sex	Male	584	19	96.7%
	Female	634	7	98.9%
Time of fixation	Immediate	351	7	98.0%
	delay(healed)	867	19	97.8%
Length	≤ 10.0	717	11	98.5%
	≥ 11.5	501	15	97.0%
Diameter	≤ 4.0	378	12	96.8%
	≥ 4.5	804	14	98.3%
GBR	Yes	611	17	97.2%
	No	607	9	98.5%
Sum		1218	26	97.9%

• Table 3.
AnyRidge® with Super RBM surface (N : Numbers) : 2009~2012
(Courtesy by 2012 MegaGen symposium poster)**Discussion**

In this study, we investigated the survival rate of 378 AnyRidge® implants in 156 patients after loading minimum 6 months. A cumulative survival rate was 99.2%. Consequently, Anyridge® implant with Xpeed surface treatment shows successful results. Although the follow up period and numbers are less compared to our previous study, it seems that the survival rates after 6 months loading period are enough to regard implant treatment to success. Two implants were extracted before loading and one implant after loading less 6 months. All of these were large bony defects without sufficient bone. More studies with larger patient numbers needed to make AnyRidge® Implant (MegaGen Co., Korea) completely evidence based.

References

- [1] Liran Levin etc, A retrospective Evaluation of 1,387 single-tooth implants : A 6-year follow-up, J periodontal 2006; 77:2080-2083
- [2] Van Steenberghe D, Outcome and their measurement in clinical trials of endosseous oral implants, Ann Periodontal 1997; 2:291-298

98.9%

Survival rate up to 7 years of loading using Rescue® MegaGen short wide diameter implants.

Mitsias ME ⁽²⁾, Kotsiotou- Siormpa E ⁽¹⁾, Efremidis I ⁽¹⁾ and Siormpas K ⁽¹⁾

1. Private Dental Clinic, Larissa, Greece, siormpk@yahoo.gr 2. Private practice, Kolonaki, Athens, Greece. www.dental-center.eu

Object

Implant placement often becomes a very difficult task, due to the lack of bone in height and width respectively. Regionally this occurs more at the posterior maxilla and mandible too (1). In order to achieve successful and adequate osseointegration, various techniques have been introduced. More specifically sinus elevation (open and close technique), vertical augmentation, distraction osteogenesis and lateral transposition of the inferior alveolar nerve. Nevertheless these techniques for various reasons, many times are not applicable or successful (2). Short implants are defined as the fixtures with equal or less of 8 mm (3). Recently the first results have been brought up to surface regarding the survival rates and the performance of them. This study presents the 7 year results of a private clinic in Larissa, Greece.

Materials and Methods

Ninety-two fixtures (Rescue® MegaGen Co, Ltd, 377-2, Kyochon-Ri, Jain-Myun, Gyeongsan, Gyeongbok, Korea) with a length between 5,0 to 8,0 mm, and a diameter of 6,0 to 8,0 were placed from 2007-2012 (4). Seventy seven patients (34 males, 43 females aged between 26-67 years of age with average age of 52,7 years were treated) participated in this private survey. From the 92 implants, seventy three were placed in maxilla and the rest nineteen were placed in mandible; 40 of these were restored with single crowns and 52 served as abutments of fixed partial dentures. Osseointegration period was standardized as 6 months for the upper arch and 3 for the lower arch. Regarding the restoration, all implants were restored using the same laboratory and technician. The superstructure design of choice was cemented porcelain fused to metal crown.

Results

From the ninety-two fixtures only one placed in the maxilla was not successfully integrated indicating a success rate of 98,9%. The later was replaced with another implant 4 months after the removal.

ARCH/sex	MALE	FEMALE	SUM	SUCCESS RATE %
MAXILLA	33	40	73	98,6%
MANDIBLE	6	13	19	100%
TOTAL	39	53	92	98,9%

Discussion

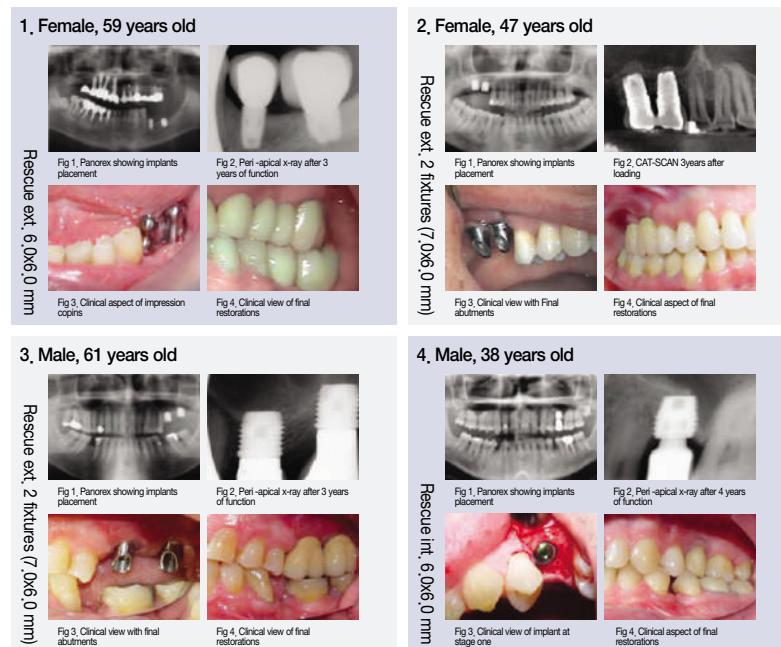
Short wide diameter implants appear as an alternative to augmentation techniques. Their advantages are: decreased cost, decreased operation time, no sophisticated surgical interventions and less complications. Their increased diameter results in an improved emergence profile which is a typical issue with standard diameter fixtures when used at a molar location. Last the increased diameter outreaches the difference in length because of the increased osseointegration surface.

Conclusions

Short wide diameter implants are a valid treatment particularly in compromised cases where an augmentative technique cannot be used, in order to have a longer implant placed. This study indicated some results as trends for the value of short implants. More studies are necessary in order these trends to become solid.

References

- Renouard F, Nisand D. Impact of implant length and diameter on survival rates. Clin Oral Implants Res 2006;17 (Suppl 2): 35-51.
- Ferrigno N, Laureti M, Fanali S. Inferior alveolar nerve transposition in conjunction with implant placement. Int J Oral Maxillofac Implants 2005; 20:610-620.
- Fugazzotto PA. Shorter implant in clinical practice rationale and treatment results. Int J Oral Maxillofac Implants 2008; 23:487-496.
- The Short Implant (from 5 to 7 mm in Length), Park KB, Roo KH, Jeong CW and Siormpas K, pp 267-291. Narae Publishing, INC.



3

3 different coating materials : Influence of implant abutment screw coating materials on joint stability

Woonchul Shin¹, Young-sun Park¹, Mongsook Vang¹, Hongso Yang¹, Sangwon Park¹, Hyunpil Lim¹, Kwi-Dug Yun¹, Hansung Joo¹

Department of Prosthodontics, School of Dentistry, Chonnam National University, Gwangju 500-757, Korea

Abstract

The aim of this study was to evaluate effect of implant abutment screw coating treatment on joint stability, investigating mechanical properties of these. For this study, ExFeel[®] external hexed implant system was used. Experimental group was 1 μ m TiN, TiCN, TiC coated abutment screws. The removal torque and rotation angle were measured after tightening up the abutment screws with 32 Ncm. The change of the removal torque was also evaluated after fatigue test. The results were as follows : rotation angle of coated screws increased than that of non-coated screw because of lower friction coefficient, especially TiC coated screw group had the largest value, but removal torque decreased in all coated screws ($p < 0.05$). Torque loss before and after fatigue test was the smallest in TiC-coated screws, and the largest in non-coated screws ($p < 0.05$), and there was no statistically significant difference between dry condition and wet condition of screws. From the above results, TiN, TiCN, TiC coating group had high abrasion resistance, especially TiC coated group which had low torque-consuming, high rotation angle as low friction coefficient will be considered to influence on implant abutment screw joint stability positively.

Background and Aim

Background : The osseointegration implant has been developed since Bränemark introduced the implant system. Recently, the success rate of the osseointegration implant is statistically over 90%. During the period of using implants, loosening is one of drawbacks of abutment screws and several methods have been attempted to prevent this problem. Various methods using abutment screw coating have been reported including not only minimize the frictional resistance but also increase the strength. TiN, TiCN and TiC have been considered as a coating material for abutment screws of implant because of their properties, but there are only few studies for applying these materials to dental field.

Aim : The aim of this study was to evaluate the mechanical properties of implant abutment screw coating treatment and the effect of this coating treatment on joint stability.

Methods and Materials

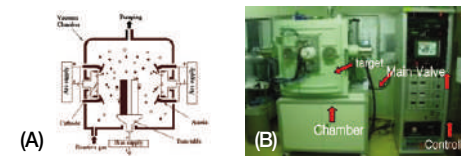
External hexed implant system (Exfeel[®], Megagen Co., Korea) were used for this study. TiN, TiCN and TiC coated abutment screws were used as experimental group and non-coated specimens were used as control group.

Group	Type of abutment screw	Coating	N
S-NC	cp-Ti gradeIII	No coating	35
S-TiN	cp-Ti gradeIII	TiN coating	35
S-TiCN	cp-Ti gradeIII	TiCN coating	35
S-TiC	cp-Ti gradeIII	TiC coating	35
Total			140

• Table 1.
Abutment screw used in present study (S : screw, NC: no coating)

After connecting abutment and fixture by tightening up the abutment screws with 32 Ncm, removal torque values were measured with MGT12(Mark-10 Corp, USA) and rotation angle were measured with Rotary encoder (Autonics, Korea). The change of the removal torque was also evaluated after 100,000 fatigue test in both wet and dry condition. All data was analyzed using Kruskal-wallis test and Mann-whitney U test with SPSS 12.0 software ($p < 0.05$)

For TiN, TiCN, TiC coating, the arc ion plating technique were used with AIP-MC-STD-300(Atek system, Korea)



• Fig 1. a) Schematic diagram of arc ion plating(AIP) apparatus
b) Arc ion plating system



• Fig 2. The device which is designed for the fatigue test

Results

Rotation angle of coated screws was greater than that of non-coated screws. Especially TiC coated screw group had the largest value ($p < 0.05$).



a - d : different with statistical significance
by Kruskal-wallis & Mann-Whitney U test ($p < 0.05$)

a' - c' : different with statistical significance
by Kruskal-wallis & Mann-Whitney U test ($p < 0.05$)

• Fig 3. Removal torque and rotation angle tested in dry condition (N=8)

Screw	S-NC		S-TiN		S-TiCN		S-TiC	
	Removal torque (Ncm)	Rotation angle (°)	Removal torque (Ncm)	Rotation angle (°)	Removal torque (Ncm)	Rotation angle (°)	Removal torque (Ncm)	Rotation angle (°)
Mean	31.6	52	30.7	52.5	27.6	54.5	30.4	55.4
SD	0.78	2.2	1.33	1.51	1.27	1.2	1.24	1.77

• Table 2.

Removal torque and rotation angle after abutment screw were tightened with 32 Ncm in wet condition (N=8)

In contrast, the removal torque of experimental group was lesser than that of control group ($p < 0.05$). Torque loss after fatigue test in coated screws was higher than non-coated screws ($p < 0.05$) and there were no statistically significant difference between dry and wet condition

Cycling loading	S-NC	S-TiN	S-TiCN	S-TiC
0	a 31.35±0.77	b 31.20±1.27	28.5±0.63	c 31.00±0.43
100,000	a,a' 26.97±0.85	b,b' 26.47±0.57	c' 27.42±1.07	c,a'-c' 29.35±0.42

a-c, a' -c' : different with statistical significance ($p < 0.05$)

• Table 3. Removal torque value according to number of cyclic loading in dry condition (N=5, mean±SD) by Kruskal-Wallis & Mann-Whitney U test

Cycling loading	S-NC	S-TiN	S-TiCN	S-TiC
0	30.27±0.51	30.83±0.69	29.5±0.59	30.58±1.02
100,000	29.37±1.78	26.7±0.32	27.57±0.3	30.58±1.02

• Table 4. Removal torque value according to number of cyclic loading in wet condition (N=5, mean±SD) by Kruskal-Wallis & Mann-Whitney U test

Conclusions

TiC coated abutment screws have low torque-consuming and high rotation angle because of its low friction coefficient. For this reason, TiC coating treatment will be considered as an efficient method to effect on joint stability of implant abutment screw.

References

- Ekfeldt A., Carlsson G.E, Borjesson G: Clinical evaluation of the single-tooth restoration supported by osseointegrated implant. Int. J. Oral Maxillofac. Implant 1994; 9:179-183.
- Elias C.N, Figueira D.C, Rios P.R. "Influence of the coating material on the loosening of dental implant abutment screw joints". Materials science & engineering :6-11, 2005
- Shigley J. Mechanical Engineering Design,ed3. New York: McGraw Hill 1987;227-52.
- Burguette RL., Johns RB, Patterson EA, King T. Tightening characteristics for screwed joints in the osseointegrated dental implants, J Prosthet Dent 1994;71:849-851.
- heol- in Koo, Chae-heon Chung, Han-cheol Choe. Effects of surface coating on the screw release of dental implant screw:KJPD 2004;42:2:210-225.
- Jai-young Koak, Seong-joo Heo, Ik-tae Chang, Soon-ho Yim, Jong-yeop Lee, Kwang-ryeol Lee. The study of the removal torque of the diamond like carbon coated titanium abutment screws:KJPD 2003;41:2, 128-135.

108.13 vs 32.63

What is the criteria for decision of proper time for prosthetics?

Youn-Kang Jung, Sung-Koog Jung, Seung-Yeup Lee, Kwang-Bum Park

Daegu Mir dental hospital in Korea

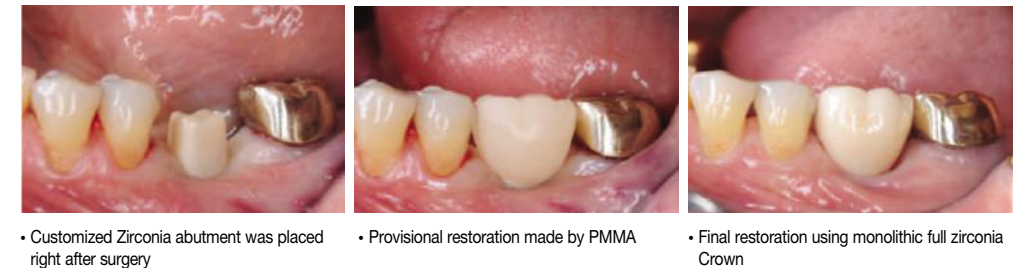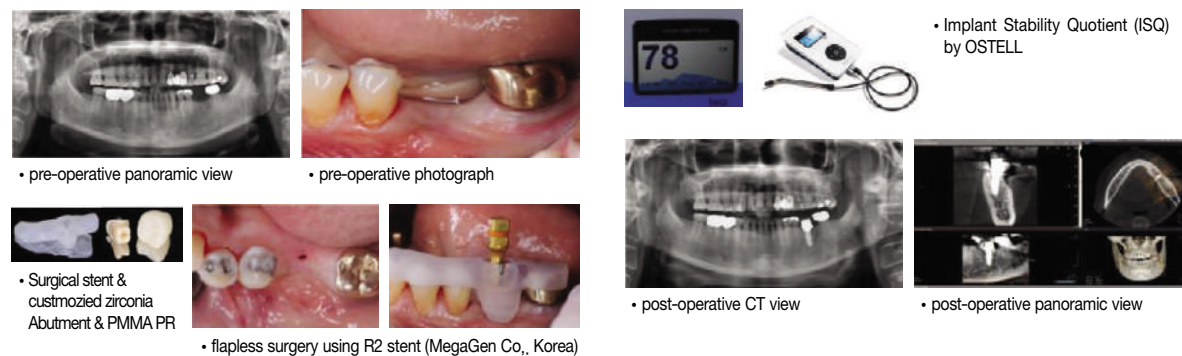
Introduction

For the long time, there has been a lot of controversies on when the possible time implants are to be loaded after placement. On average, general prosthetic procedure were recommended to start loading in 4 to 6 months in maxilla and 3 to 4 months in mandible after surgery, respectively. In most cases, we used to make the decision of proper time for prosthetics depending on clinician's feeling or radiographs. Recently, advanced implant surface treatment technology, implant designs and surgical placement technique for promoting initial stability would have enabled to reduce time for osseointegration but still no objective standards. The Implant Stability Quotient (ISQ) is a useful source that indicates the level of stability and osseointegration in dental implants. This is measured by special instruments using RFA (Resonance Frequency Analysis) technique and ranges from 1 to 100. The acceptable stability range lies between 55-85 ISQ[1]. The overall average ISQ value of all implants over time is approximately 70[2]. A significant decrease in ISQ indicates a potential problem and should be considered an early warning [3]. In this study, we investigated that the survival rates of Anyridge implant with deep and knife thread, which ISQ value is more than 70 right after surgery or treated Xspeed surface treatment in 25 cases of healed ridge after loading 1 year.

Materials & Methods

The retrospective study group was comprised of 50 implants treated in Daegu Mir dental hospital between May 2012 and April 2013. The control groups were composed of 25 AnyRidge implants (without ISQ value)(MegaGen Co., Korea)were placed between May 2012 and August 2012 (12 male/13 female, mean age 62.72) and the test groups were 25 AnyRidge implants (7 male/18 female, mean age 59.92) treated with Xspeed surface (using ISQ) between November 2012 and April 2013. In test groups, ISO value were measured from implant placement to delivery of prosthetics every week. If the ISQ value which measured right after surgery was under 70, that was excluded from research. And if the ISQ value continue to decrease under 70 during follow up period, that was also not be selected.

Case Report



Results

25 implants in control group showed the average 108.13 day from implant placement to delivery of prosthetics. At this time, we made the decision of proper time for prosthetics depending on radiographs, experiences and recommendation. Compared to this, the test group showed the average 32.63day (67.89 day without immediate loading) from implant placement to delivery of prosthetics. The ISQ value was measured every week right after surgery. In test groups, the mean ISQ value was 76 in buccal side and 76 in lingual side respectively. There were no failure on both side.

• Table 1. average periods from implant placement to delivery of prosthetics and ISQ value.

	The day between fixture insertion and abutment insertion	Mean ISQ value (at fixture insertion)
without ISQ	108.13 day	
with ISQ	32.63 day 67.89 day (without immediate loading)	76(B) 76(L)

• Table 2.

	Control group (without ISQ, total 25)	Test group (with ISQ, total 25)
Male / Female	12 / 13	7 / 18
Flapless / Non flapless	6 / 19	5 / 20
Immediate loading / Non immediate loading	4 / 21	15 / 10
Failure	0	0

In the past, we made the decision of proper time for prosthetics depending on radiographs, experiences and recommendation. Recently, many studies have been reported that the ISQ value provide objective data about stability of implant and is effective for decision of loading time. Resonance frequency analysis stability measurements essentially apply a bending load, which mimics the clinical load and direction and provides information about the stiffness of the implant-bone junction. Other techniques, such as the Periotest also aim to provide an objective measure of implant stability and osseointegration that is noninvasive and does not damage the implant-tissue interface.

Actually, higher ISQ value measured right after surgery doesn't mean that the osseointegration is completed. A cumulative survival rate was 100%. More studies with larger patient numbers needed to make the decision of proper time for prosthetics completely evidence based. Despite more research needed, in this research, it seemed that ISQ value is more effective for clinicians to determine when is the possible time implants to be loaded after placement.

References

- 1 Sennerby L, Meredith N. Implant stability measurements using resonance frequency analysis: biological and biomechanical aspects and clinical implications. Periodontology. 2000; 2008
- 2 Sennerby L, Meredith N. Implant stability measurements using resonance frequency analysis: biological and biomechanical aspects and clinical implications. Periodontology. 2000; 2008
- 3 Glauser R, Lundgren AK, Gottlow J, Sennerby L, Portmann N, Ruhstaller P, Hamerle CH. Immediate occlusal loading of Branemark TiUnite implants placed predominantly in soft bone: 1-year results of a prospective clinical study. Clin Implant Dent Relat Res. 2003;5 Suppl 1:47-56

1,5

1,5 mm of Buccal Bone Width Prevents Bone Resorption: Perspective evaluation on 84 consecutive cases

Davide Farronato¹, Andrea Alain Orsina², Pietro Mario Pasini², Filippo Ferretti², Eleonora Pionati³, Giada Goffredo³, Davide Fumagalli⁴

¹ Assistant Professor, University of Insubria, Department of Surgical and Morphological Science, Italy

² Resident, University of Insubria, Department of Surgical and Morphological Science, Italy

³ Student, University of Insubria, Department of Surgical and Morphological Science, Italy

⁴ Student, University of Milan, School of Dentistry, Italy

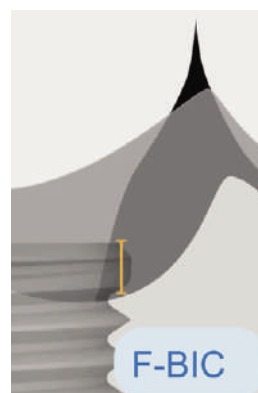
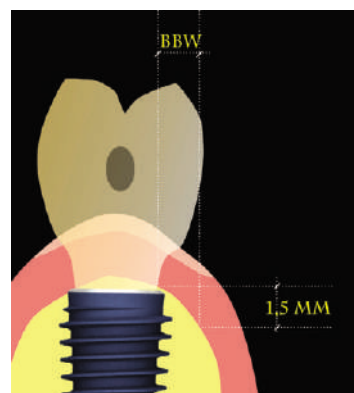
Object

This perspective study is aimed to evaluate the soft-tissue maturation around titanium implants. In detail the influence of the residual facial bone thickness at implant placement time on the buccal gingival zenith stability.

Materials and Methods

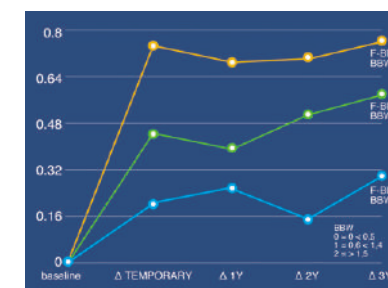The study includes 84 consecutively enrolled implants. The total follow-up time is 3 years with a planned evaluation at provisional placing (baseline) and 1,2,3 years.

All implants were clinically and radiologically monitored at each year follow-up and data regarding facial mucosa height (HG, the distance between the gingival zenith and the incisal edge of the prosthetic restoration) and 4 points probing depth were collected. Buccal bone width (BBW) value was evaluated during surgery and was recorded after implant placement. All data were then inserted in a statistical software (SPSS 20, IBM) and processed. Afterwards delta, mean and statistical correlation results were analyzed (Pearson Two-Tailed 95% Conf. Int.).



Results

At the third year follow up, it is observed that for a buccal bone width $\geq 1,5$ mm the buccal zenith of the corresponding implant creeps by an average of +0,59 mm. For a buccal bone width from 0,6 to 1,4 mm the average gingival zenith value results -0,78mm shrunk and when buccal bone width is $< 0,5$, the zenith recedes by an average -1,13 mm. Results were observed to be statistically significative ($p=0,002$) (Pearson Two-Tailed 95% Conf. Int.).



Δ AVERAGE	baseline	ΔEPR	Δ1Y	Δ2Y	Δ3Y
F-BIC BBW 2	0	0,20	0,24	0,15	0,30
F-BIC BBW 1	0	0,44	0,39	0,50	0,57
F-BIC BBW 0	0	0,75	0,70	0,71	0,76
N	84	84	84	84	84
p (Pearson 2Tailed)	0,597	0,014	0,039	0,074	0,209

Conclusions

Whenever a correct surgery is made, patient's domiciliary maintenance is observed and good prosthetic design is reached, buccal bone width at implant placement plays a cutting edge role on gum parable stability over time. In the 84 considered cases the relation is confirmed and a wider buccal bone width is favorable whenever is possible. Implant designs that preserve bone width should be the first choice and wherever buccal bone width is below 1,5 mm guided bone regeneration techniques are mandatory to overcorrect the buccal plate in order to achieve a highly predictable tissue stability around implants.

References

- 1 Linkevicius T, Apse P. Biologic Width Around Implants. An Evidence-Based Review. Stomatologija. 2008;10(1):27-35.
- 2 Tarnow DP, Cho Sc, Wallace SS. The effect of interimplant distance on the height of interimplant bone crest. J Periodontol. 2000 Apr;71(4):546-9.
- 3 Albrektsson T, Zarb G, Worthington P, Eriksson AR. The long-term efficacy of currently used dental implants: A review and proposed criteria for success. Int J Oral Max. Imp. 1986;1:11-25.
- 4 Farronato D, Santoro G, Canullo L, Maiorana C, Botticelli D, Lang NP. Establishment of the epithelial attachment and connective tissue adaptation to implants installed under the concept of "Platform switching" - A histologic study in minipigs. Clin Oral Implant Research. 2012;23:90-4.
- 5 Hermann J, Buser D, Schenk RK, Schoolfield JD, Cochran DL. Biologic width around one-and two-piece titanium implants. A histometric evaluation of unloaded nonsubmerged and submerged implants in the canine mandible. Clin Oral Implants Res 2001;12:559-571.

100 %

Success rate of the “Root Membrane” Technique using AnyRidge® implants after 3 years of loading

Siormpas K^[1], Kontsiotou- Siormpa E^[1], Gasparatos S^[2], Kotsakis G^[3], Mitsias ME^[2]

1. Private Dental Clinic, Larissa, Greece, siormpk@yahoo.gr.

2. Private practice, Athens, Greece, www.dental-center.eu

3. Fellow, International Congress of Oral Implantologists (ICOI), Advanced Education Program in Periodontology University of Minnesota, MN, USA

Introduction

During the immediate post-extraction period the buccal plate of a maxillary anterior dentition is leading to significant dimensional alterations (Braut et al. 2012). Ridge preservation techniques limit but do not counter ridge resorption (Kotsakis et al. 2014). Immediate implant placement does not prevent ridge resorption (Lee et al. 2014). Loss of blood supply derived from the periodontal ligament (PDL) has been identified as a major etiologic factor for ridge resorption (Kotsakis et al. 2014). Root submergence has been utilized for over 40 years to ensure hard and consequently soft tissue dimensional stability (Salama et al. 2007). Animal studies and case reports provide proof-of-principle data on the feasibility of immediate implant placement in proximity to a retained root fragment for the strategic preservation of the natural tooth apparatus (Hurzel, et al. 2010). The “Root membrane” technique relies on the preservation of PDL, buccal plate and facial soft tissue esthetics via selective preservation of the buccal portion of the root (Mitsias et al. 2014). Recently, the first longitudinal data on implant success using this technique for immediate implant placement in maxillary anterior sites was presented (Siormpas et al. 2014).

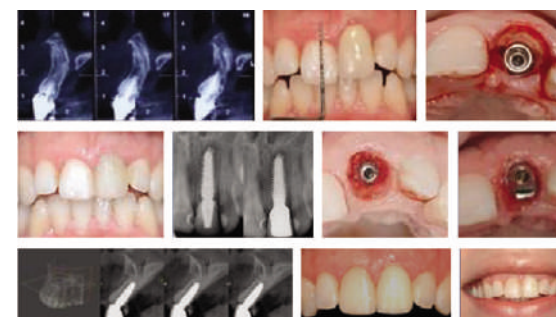
Materials and Methods

Forty-four fixtures (N=44) (AnyRidge® MegaGen Co, Ltd, 377-2, Kyochon-Ri, Jain- Myun, Gyeongsan, Gyeongbuk, Korea) with a length between 10 to 13 mm, and a diameter of 3,5 to 4,5 mm were placed from 2010-2012. Forty patients (N=40) (17 males and 23 females aged between 25-66 years of age with an average age of 48,7 years) participated in this private study. All implants were immediately loaded with a cement-retained chairside acrylic provisional restoration. The final superstructure design of choice was a cemented PFM from the same laboratory and technician for all patients. The crown of the involved tooth was removed with a conventional chamfer diamond bur under copious irrigation until the remaining tooth structure was leveled one millimeter above the osseous crest. The reason for not reducing it at the level, or even below the osseous crest was to maintain the dentogingival fibers intact to enhance soft tissue esthetics. The osteotomy sites were prepared by drilling through the long axis of the roots. This technique implements with gradual intraroot extraction (dentinotomy - osteotomy) of the palatal aspect of the root following the drilling sequence suggested by the implant manufacturer.

Results

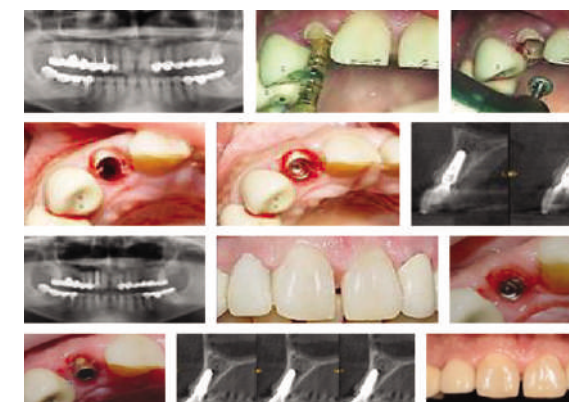All forty-four fixtures were successfully integrated indicating a success rate of 100%. CBCT evaluation indicated that there was no bone loss during this period of time regarding the alveolar ridge.

1, Female, 32 years old



- Fig 1, Initial cat-scan (horizontal fracture of tooth).
- Fig 2, Initial clinical view
- Fig 3, Implant placement in contact with retained part of the root
- Fig 4, Provisional restoration
- Fig 5, X-ray after implant placement and after the final restoration
- Fig 6, Peri- implant tissue
- Fig 7, Final abutment in place
- Fig 8, Cat-scan 3 years after post loading
- Fig 9, The final restoration in post.
- Fig 10, Final esthetic result.

2, Female, 50 years old



- Fig 1, Initial panorex
- Fig 2, Initial osteotomy
- Fig 3, Sequential osteotomy
- Fig 4, Final osteotomy
- Fig 5, Implant in place
- Fig 6, Cat-scan of implant placement
- Fig 7, After post loading
- Fig 8, Provisional restoration
- Fig 9,10, Tissue configuration - final abutment
- Fig 11, Cat-scan 3 years after post loading
- Fig 12, Final esthetic result

ARCH/sex	PATIENTS	ANYRIDGE IMPLANTS	SUCCESS RATE %
MALE	17	19	100
FEMALE	23	25	100
TOTAL	40	44	100

Conclusions

The ‘Root membrane technique’ (immediate implants placement and loading in the aesthetic zone of the maxilla), has been proven to be a successful alternative method for the aesthetic preservation of the tissues in this demanding area. More studies have to take place in order to establish this trend technique as a validated scientifically surgical procedure.

References

- [1] Braut, V., Bornstein, M. M., Lauber, R. & Buser, D. (2012) Bone dimensions in the posterior mandible: A retrospective radiographic study using cone beam computed tomography. Part 1—analysis of dentate sites. *Int J Periodontics Restorative Dent* 32: 175-184.
- [2] Kotsakis GA, Salama M, Chrepa V, Hinrichs J, Gaillard P. A randomized, blinded, controlled clinical study of particulate Anorganic Bovine Bone Mineral and Calcium Phosphosilicate Putty bone substitutes for alveolar ridge preservation. *Int J Oral Maxillofac Implants*. 2014 Jan-Feb;29(1):141-51
- [3] Hurzeler MB, Zuh O, Schupbach P, et al. The socket-shield technique: a proof-of-principle report. *J Clin Periodontol* 2010;37(9):855-62.
- [4] Mitsias, M, Siormpas, K, Kontsiotou- Siormpa E, Prasad H, Garber, D, Kotsakis GA. A step-by-step description of immediate implant rehabilitation in the esthetic region utilizing the “Root-membrane” technique. *Int J Periodontics Rest Dent*, February 2014 [In Press]
- [5] Salama et al. Root submergence has been utilized for over 40 years to ensure hard and consequently soft tissue dimensional stability. *Int J Periodontics Restorative Dent*. 2007 Dec;27(6):521-7.
- [6] Siormpas, K, Mitsias, M, Kontsiotou- Siormpa E, Garber, D, Kotsakis GA. Immediate implant placement in the esthetic zone utilizing the “Root-membrane” technique: clinical results up to 5 years post-loading. *Int J Oral Maxillofac Implants*. 2014 Nov-Dec;29(6):1397-05.

0,66mm

SHORT-TERM MARGINAL PERI-IMPLANT BONE LOSS ASSOCIATED WITH PLATFORM SWITCHED IMPLANTS: A PROSPECTIVE COMPARATIVE SPIT MOUTH STUDY.

Alessandro Rossi*, David Palombo*, Luigi Tagliatesta*, Andrea Flora, Vincenzo Capilupi*, Matteo Chiapasco*

* Unit of Oral Surgery (Head Prof. M. Chiapasco), Department of Health Sciences, San Paolo Hospital, University of Milan, Italy

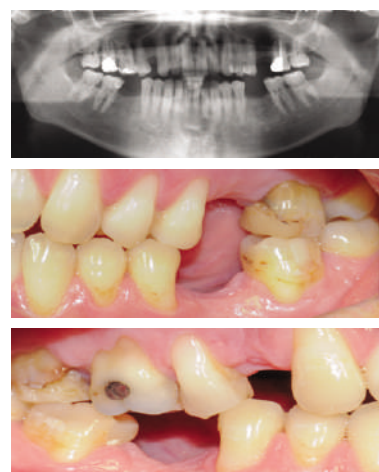Objectives

To inquire regarding the presence of significant differences between platform matched and platform switched implant connections, with respect to the development of peri-implant saucerization and to its extent.

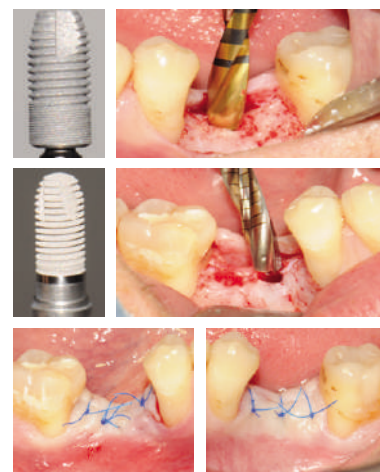
Materials and Methods

From 2012 to 2014, 10 patients (4 males and 6 females, aged between 23 and 59 - mean 40,9 years), presenting with single tooth symmetric bounded edentulous spaces in the posterior maxilla or mandible, were treated with the insertion of a platform matched implant (BEGO Semados® S-Implants, BEGO Implant Systems™) in one site and of a platform switched implant (OsseoSpeed® TX 4.0 S, Astra Tech Implant System™) in the symmetric contralateral one. All edentulous sites did not require bone regeneration in order to place 4mm implants with a minimum length of 8mm. All patients received implants with matching lengths in the two symmetric sites. Patients were followed up from 12 to 30 months (mean 20,4) after prosthetic finalization.

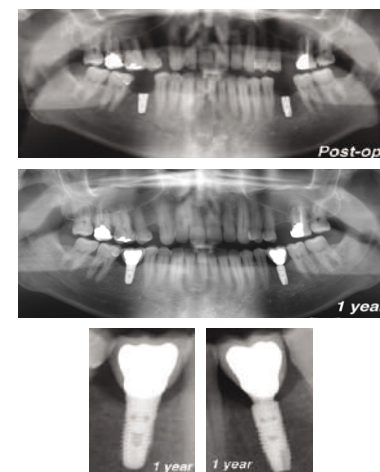• Fig 1-3. Pre-operative OPT and clinical evaluation



• Fig 4-8. Implants placement



• Fig 9-12. Radiographic follow-up



Group	N of implants	Mean Follow-up	Mean FMPS	Mean FMBS	Mean PPD	Mean Peri-Implant Vertical Bone Resorpton	% Implant Success	% Implant Survival
Control	10	20,4 months	16%	8%	3,9 mm	2,14 mm	2,14 mm	100%
Study	10	20,4 months	16%	8%	3,63mm	0,66 mm	0,66 mm	100%

Results

All patients were evaluated at their last recall with a periodontal chart and a periapical radiograph, standardized through the customization of a Rinn's film holder. No implant was lost or removed. A single patient, presenting at the one year recall with inadequate oral hygiene, reported severe peri-implant bone resorption in both sites treated. 9 out of 10 patients reported successful outcomes according to Albrektsson et al. criteria. Periodontal probing revealed no significant differences between study and control sites (study group: mean 3,63mm; control group: mean 3,9mm). However, the evaluation conducted on the periapical radiographs through an image processing and analysis software, revealed a consistent reduction in the extent of vertical peri-implant marginal bone resorption around the platform switched implants (mean 0,66 mm) compared to the platform matched ones (mean 2,14 mm). Such difference was observed in almost all patients at different follow-up times from prosthetic finalization, suggesting how the benefits of a platform switched connection can be observed both at a short term (12 months) and longer term (30 months) follow-ups.

Conclusions

Results from this study suggest that a platform switched implant connection can reduce the extent of vertical peri-implant marginal bone resorption, thus containing the saucerization process commonly observed around two-piece submerged platform matched implants.

References

- [1] Cochran, D.L., Hermann, J.S., Schenk, R.K., Higginbottom, F.L. & Buser, D. (1997) Biologic width around titanium implants. A histometric analysis of the implant-to-gingival junction around unloaded and loaded nonsubmerged implants in the canine mandible. Journal of Periodontology 68: 186-198.
- [2] Gardner DM. Platform switching as a means to achieving implant esthetics. N Y State Dent J 2005;71:34-7.
- [3] Hermann, J.S., Cochran, D.L., Nummikoski, P.V. & Buser, D. (1997) Crestal bone changes around titanium implants. A radiographic evaluation of unloaded nonsubmerged and submerged implants in the canine mandible. Journal of Periodontology 68: 1117-1130.
- [4] Quirynen M, Bollen CM, Eyssen H, van Steenberghe D. Microbial penetration along the implant components of the Branemark system. An in vitro study. Clinical Oral Implants Research 1994;5:239-44. 0,66mm

21 PATIENTS SINUS LIFT

SINUS LIFT CRESTAL APPROACH (MICA-KIT) : TECHNICAL DESCRIPTION AND CASE SERIES

Oscar Alonso Gonzalez, MD, DDS¹. Santiago Pasquín C de Sobregrau, MD, DMD^{1,2}, Ramon Buenechea Imaz, MD, DMD, PHD¹. Meritxell Losada Martinez, DDS, MS^{1,3}

1. Private practice, BCN Spain, .WWW.clinicadentalbarcelona.com
2. Departament of Prosthodontics, Universitat de Barcelona
3. Departament of periodontics, International University of Catalunya

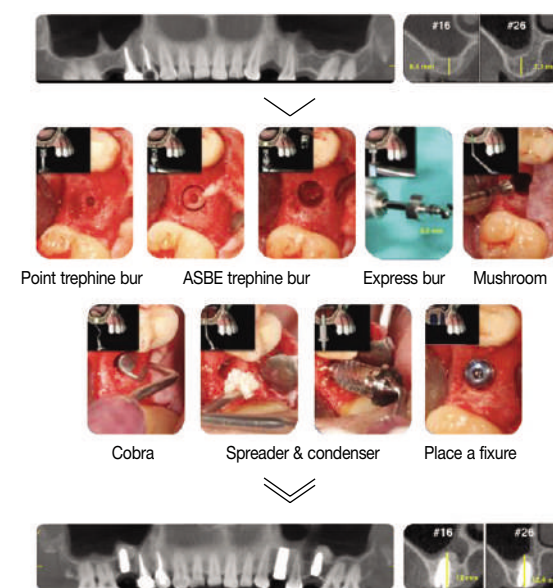
Object

The aim of this study is to present a nouvelle crestal approach sinus lift technique (MICA).

Materials and Methods

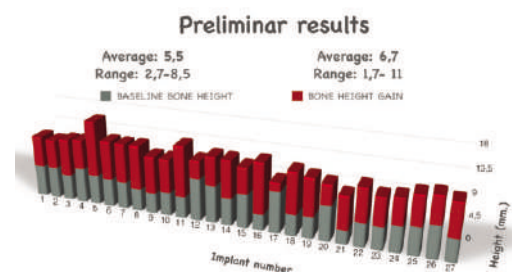
A total of 27 implants were placed in 20 patients (13 female and 7 male) through a MICA crestal sinus lift technique (Megagen). Autogenous bone graft in combination with xenograft were used to regenerate the sinus in all the cases. The baseline height and width of the ridge were recorded preoperative by CBCT imaging. At the end of the surgery, another CBCT was performed to measure the final height achieved with MICA technique. Surgery complications and implant failure were recorded during a period of 2 to 22 months of follow-up.

Technical description



Preliminar results

- patients number: 21
- implants number: 27
- implant position:
 - 2nd premolar: 3
 - 1st molar: 17
 - 2st molar: 7
- implant dimensions:
 - 5x10: 25
 - 5x8,5: 1
 - 4x10: 1
- prosthesis:
 - single crown: 6
 - bridge: 21
- membrane perforations: 1
- implant failure: 0



Results

Only preliminar results are presented in order to show the bone height gain with this technique and the implant survival rate during 22 months. The average width of the ridge was 10.4 mm (range of 7 to 15,2 mm). The average initial height was 5.5 mm (range 2.7 to 8.5 mm). The final average height was 12,1 mm (range 9.3 to 17 mm). The average height bone gain was 6.7 mm (range 1,7 to 11 mm). Twenty-six implants were wide platform (25 implants of 5x10mm and 1 implant of 5x 8,5mm), and one implant regular platform (4x10 mm).

The only complication recorded was a membrane perforation without affecting implant survival.

Conclusions

The crestal sinus lift MICA technique demonstrated low intraoperative and postoperative complications. The smooth drilling of the specific bur (express bur) and the membrane raising with Cobra instrument offers a direct tactile and visual control of the membrane during all the procedure.

References

- 1 Louie AL Faraje, DDS. Surgical Anatomy and Radiology Oral Implantology
- 2 Esposito M1, Grusovin MG, Rees J, Karasoulos D, Felice P, Alissa R, Worthington H, Coulthard P. Effectiveness of breast lift procedures for dental implant rehabilitation: a systematic review Cochrane. Eur J Oral Implantol. 2010 Spring; 3 (1) :7-26.
- 3 Pjetursson AT1, , D, Matuliene. Maxilla transalveolar endoscopy afford more lift most of the maxillary sinus through osteotomes with or without graft material. Part II: Ray tissue remodeling. Clin Res Oral implants, Jul 2009; 20 (7) :677-83.
- 4 G, Brägger U, Schmidlin K, Lang. Nkenke E1, Stelzle F. . The clinical results of elevation of the use of autogenous bone implants or bone substitutes ½ eos: a systematic review. Clin Res Oral implants, 2009 Sep;20 Suppl 4:124 -33.
- 5 R. B. Summers, "an osteotome behind technical: part 3-less invasive to raise the floor of the womb", Digest, vol 15, no. 6, Pp. 698-710, 199.
- 6 Peñarocha' s Guantanamero M, Perez H, Garcia A, Guarinos J. Benign paroxysmal positional vertigo as a complication of an osteotome behind expansion of the maxillary alveolar ridge. J Oral Maxillofac Surg 2001; 59:106-107.
- 7 Samuel Lee, DDS *, Grace Kang-Lee, DDS, Kwang-Bum Park, DDS, MS, PhD, Thomas have, DDS, "MS window crestal sinus lift", minimally invasive, predictable and systematic approach for grafting.

1 connection

3D-planning makes it possible to design and manufacture a definitive abutment and immediate placement after implant insertion

Dr. Irfan Abas, prosthodontist & implantologist

Private practice, Bussum, the Netherlands

Introduction

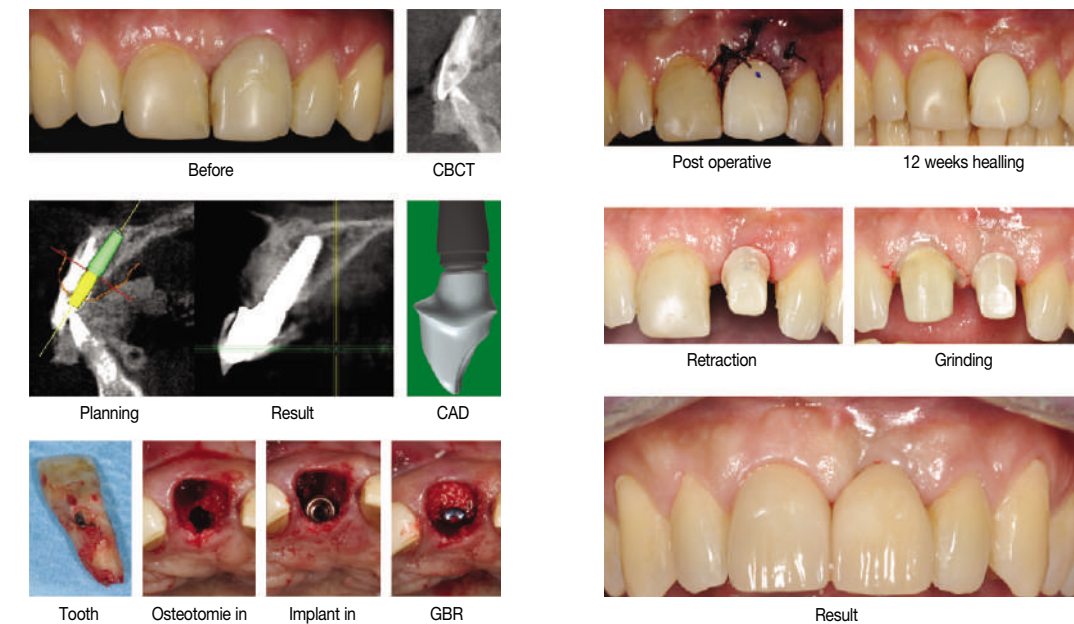
After the loss of a tooth, an implant can be placed immediately, early (after 6-8 weeks) or late (after 3 months)¹. In the mean time a provisional restoration is mandatory. By placing an implant and immediate loading with a temporary abutment and crown, a temporary solution becomes unnecessary.

Objective

To place a definitive abutment after implant insertion and to make the use of a temporary abutment unnecessary. MegaGen Implant Company (Daegu, Korea) has recently developed the concept of "One Day Implant". In their software planning R2GATE the DICOM-files of a CBCT-scan are combined with STL-files to assure higher accuracy. With the use of R2GATE you can determine the implant position with guided surgery, as well as CAD/CAM of your definitive Zirconia abutment and temporary crown. The advantage of this treatment is that one connection of the abutment is made to the implant. As Degidi et al, showed in 2011 that non-removal of abutments resulted in significantly less reduction in horizontally bone remodeling². Also with the use of guided surgery the chance of achieving a high initial stability is higher. As literature shows that after achieving an insertion torque of 35N/cm² or higher, there is no significant difference in implant failure between conventional or immediate loading in rough surface implants³.

Method

A 33-year old healthy male patient had a bad prognosis on tooth 21 due to internal resorption (trauma) and endodontically treated. After carefully extraction of the 21, an implant (MegaGen AnyRidge 4,0x13 mm) was placed in the palatal wall of the alveole with an insertion torque of 50N/cm² and an ISQ-value of 75. After implant placement the buccal alveole and gingiva were reconstructed by means of a bovine bone derived xenograft (Bio-Oss®) and a connective tissue graft harvested from the palate. The definitive CAD/CAM Zirconia abutment was then placed with a torque of 35N/cm² and the temporary PMMA-crown was cemented with a temporary cement (Tempbond®). After an osseointegration period of 4 months, there was a slight retraction of the soft tissue. The shoulder of the Zirconia abutment was then grinded together with a crown preparation of tooth 11 and silicone impressions were then made with a closed tray. Two feldspathic ceramic crowns were made and cemented adhesively.



Results

It was possible to place a definitive Zirconia abutment together with implant placement with the advantage that the abutment-implant seal stays intact. Some retraction of the periimplant mucosa did occur, but this could be corrected by grinding the Zirconia abutment.

Conclusions

3D planning makes it possible to place an implant and a definitive abutment at the same time.

References

- ① Esposito et al, Cochrane Database Syst Rev 2010 Sep 8;(9)
- ② Degidi et al, Clin. Oral Impl. Res. 22, 2011/1303-7
- ③ Engelhardt, Papacosta et al, Clin. Oral Impl. Res. 00 2014,1-17

1 Surgery 1 Time

Whats in you're toolbox

Dr Isaac Tawil, Dr David Tawil

Object

42 tear old healthy female patient presented requesting fast cosmetic and functional makeover for upcoming event in 7 months time. Full mouth rehabilitation and implant therapy in under 6 months time was treatment planned. This included perio and restorative dentistry followed by cosmetic and implant therapy. In addition removal of remaining molars with simultaneous sinus augmentation of the upper left quadrant, and ridge augmentations in both lower quadrants to facilitate individual teeth.

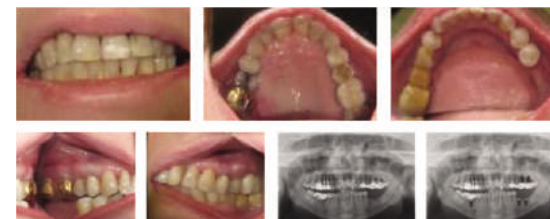Materials and Methods

In the upper left quadrant hopeless molars were removed and sinus express bur from MICA kit was used to access the schneiderian membrane from a crestal position. Sinus membrane was lifted with mushroom and cobra instruments from MICA kit and approximately 12-15mm of height was gained, FDBA with autogenous fibrin glue aka, sticky bone, along with immediate AnyRidge implants 5×11.5 and 5×10 were placed.

Ridge splitting of lower left region using piezoelectric motor and AnyRidge implants for bone expansion 4×10 mm respectively. No bone substitute was added only PRF for wound closure and tissue enhancement.

On the lower right quadrant fixed partial denture was removed. Endodontic therapy of the 2nd bicuspid was performed along with placement of AnyRidge implant into the molar site, 4.5×10 mm implant was used decortication of residual bone and harvesting of autograft from external oblique ridge were performed using automax burs. i-Gen membrane secured the graft along with healing abutment facilitating primary wound closure.

Object

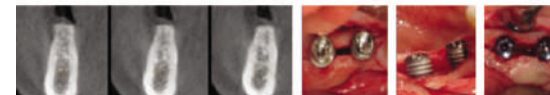


Materials and Methods

- Sinus augmentation



- Ridge splitting



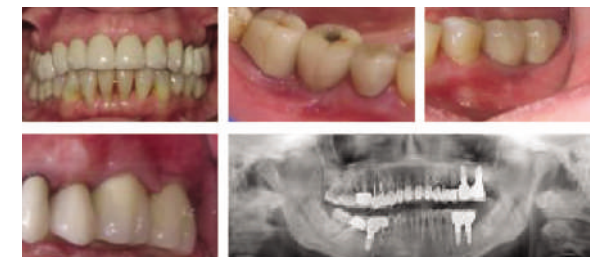- i-Gen/Auto-Max



Results

4 Months post operatively implants were exposed, ostell readings were taken. All implants received ostell scores of 78 and above, temporary prosthetics were delivered. At 5.5 months final restoration were inserted. Panoramic image and photos post op 18 months.

Results



Conclusions

MegaGen sinus, harvesting and augmentation kits can facilitate faster, simpler and more efficient surgical procedures to shorten treatment time and increase efficiency.

References

- [1] Simion M, et al Jawbone enlargement using immediate implant placement associated with a split-crest technique and guided tissue regeneration. Int J of Perio Restorative Dentistry 1992;12(6):462-73
- [2] Misch CE :Maxillary sinus augmentation for endosteal implants, Int J Oral Implant 1987;4:49-58.

3

Three ways of predicting the implant primary stability : Torque, ISQ and bone density accessed by CBCT. Results of Randomised Controlled Trial (RCT).

RAQUEL ZITA GOMES, ANTONIO FELINO, LAURA SILVA, JOAO COIMBRA, ANDRE CORREIA, RICARDO TAVARES, MARIO VASCONCELOS

Introduction

The success of oral rehabilitation depends on the amount and quality of available bone. (1) Cone-Beam Computerized Tomography (CBCT) manages to determine the bone density in Hounsfield Units (HU) and to classify it, according to Misch's 5 bone-type scale. (1,2) Implant stability may be assessed non-invasively through the implant torque test or radio-frequency analysis (RFA), which evaluates the stiffness of the bone/implant complex.(2)

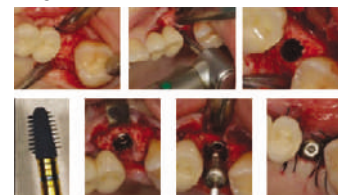
Objectives

The present RCT main aim is to evaluate whether a relationship between the amount of bone density, measured by means of CBCT in the preoperative phase, the value of insertion torque during implant placement and the implant quotient stability (ISQ) measured by radio - frequency (Osstell®) after implant placement exists.

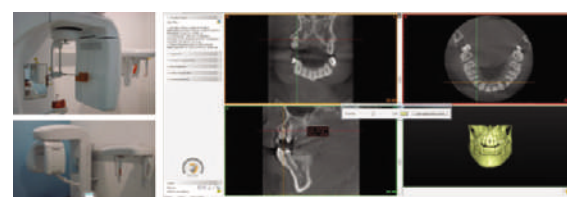Materials and Methods

Forty patients were initially gathered and the initial sample was composed of 105 implants (AnyRidge, Megagen), placed following a conventional protocol of one or two stage surgeries.(fig.1) Inclusion criteria included oral rehabilitation clinical cases with an indication of one or more implants in edentulous areas not previously regenerated with complementary diagnostic test CBCT with the possibility of analysis of bone density (by SimPlant Pro 15 software) and measurement of torque and ISQ during the implant placement. Exclusion criteria include patients with no controlled systemic diseases and with pharmacological therapies that can alter bone metabolism. After the application of inclusion and exclusion criteria the final sample was composed by 79 implants placed in 28 patients. Bone density of the precise implant location was assessed pre-surgically through CBCT, according to the Hounsfield scale (D1 to D5), through SimPlant Pro 15 program. (fig.2) Implant torque was determined during implant surgery with a Bienair® motor with a 20:1 reduction and/or the help of an implant calibrated torque key. (fig.3) RFA was expressed by the implant stability quotient (ISQ), evaluated through Osstell® analysis on two perpendicular assessments (V-L and M-D).(fig.4) The specific Anyridge smartpeg to ISQ measure was screwed using a special instrument inserted in Meg-Torque® (Megagen, Gyeongsang, Korea) portable engine calibrated at 10 N/cm.(fig.5)

• Fig 1.



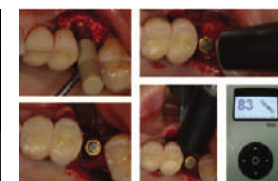• Fig 2.



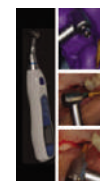• Fig 3.




• Fig 4.



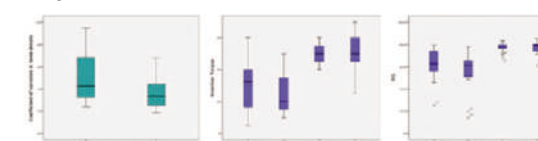
• Fig 5.



• Fig 6.



• Fig 7.



Results and discussion

Through Spearman correlation, we found a statistically significant correlation for the three relations. The coefficient of variation of bone density obtained a value of $rs=-0.322$ ($p = 0.01$) correlation with the insertion torque and $rs=-0.296$ ($p=0.005$) with the ISQ ($p = 0.010$). ISQ showed correlation value $rs=0.834$ ($p<0.05$), with the insertion torque. Also, the results from this study found a strong association between the ISQ and torque which allowed, by linear regression, the establishment of a formula ($ISQ = 51.51 + 0.49 \times \text{torque}$) that allows the prediction of one of the variables according to the other in about 74 % of cases. Thus, for example, a torque of 50 N/cm prediction is ISQ 76 ($ISQ + 0.49 = 51.51 \times 50 = 76$) (fig.4) Non-parametric tests employed for implant samples placed on the upper and lower jaw have shown statistically significant differences between bone density, implant torque and ISQ ($p<0.01$). (fig.5 - graphics) Pre-operative bone density assessment appears to be of major importance, allowing to predict the implant primary stability coordenades (torque and ISQ).

Conclusions

In our sample we proved the existence of a strong positive correlation and statistically significant ($p < 0.05$) among the three variables: bone density measured in CBCT (preoperative), insertion torque and ISQ at implant placement. The bone density measurement of the receptor site can be a criterion for predicting the implant's primary stability, making it an excellent diagnostic tool. The sum of the data values of the three variables (CBCT bone density, insertion torque and ISQ) provides an objective and measurable bone quality information as well as protocols (guidelines) to support clinical decisions. Within the limitations of this study, concerning Anyridge implants placement, presurgical CBCT mineral bone density assessment might allow one to predict implant's future stability. Of course, in the future more research is needed on this topic.

References

- 1 Isoda K et al, Relationship between the bone density estimated by cone-beam computed tomography and the primary stability of dental implants. COIR. 2012;23(7):832-6.
- 2 Bayarchimeg D et al, Evaluation of the correlation between insertion torque and primary stability of dental implants using a block bone test. JPIS. 2013;43(1):30-6.

2 years

IMMEDIATE FUNCTIONAL LOADING OF SINGLE ANYRIDGE® IMPLANTS A 2-YEAR PROSPECTIVE MULTICENTER STUDY

MANGANO F¹, LUONGO F², RAES F³, LENZI C⁴, ECCELLENTE T⁵, ORTOLANI M⁶, LUONGO G⁷, MANGANO C⁸

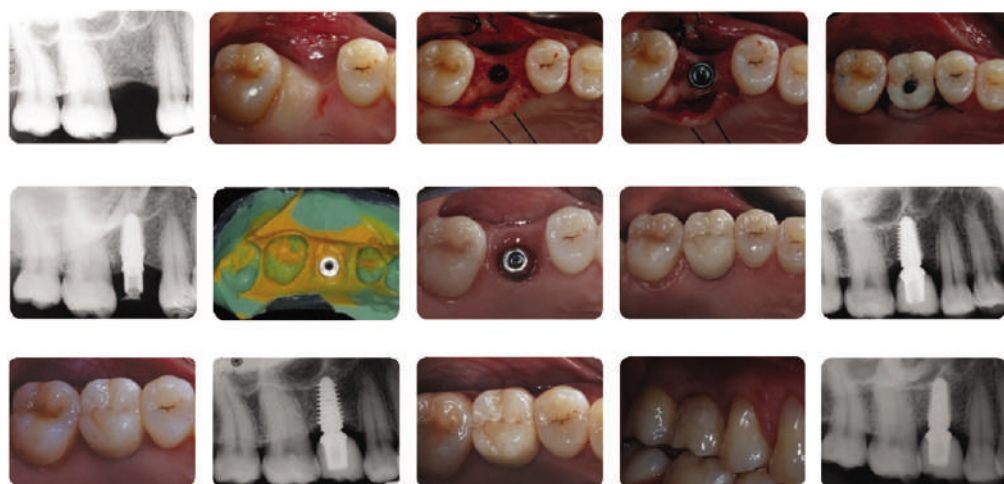
1. Department of Surgical and Morphological Science, Dental School, University of Varese, Italy
2. Private Practice, Rome, Italy
3. Department of Periodontology and Oral Implantology, University of Ghent, Belgium
4. Private Practice, Bologna, Italy
5. Private Practice, Grumo Nevano, Italy
6. Private Practice, Naples, Italy
7. Department of Oral and Maxillofacial Surgery, Dental School, University of Naples, Italy
8. Department of Oral and Biotechnological Sciences, Dental School, University of Chieti, Italy

Objectives

The aim of the present prospective multicenter study with 2 years of follow-up was to evaluate the clinical outcome of immediately loaded single AnyRidge® implants.

Materials and Methods

Patients were recruited at six clinical centers. Inclusion criteria were single tooth replacement in fully healed sites or post-extraction sockets with adequate bone height and width to place an implant of at least 3.5 mm in diameter and 10.0 mm in length. All implants (AnyRidge® implants, Megagen) were functionally loaded immediately after placement. After 3 months, final crowns were delivered. All implants were followed for 2 years. Outcome measures were: implant stability, complications, peri-implant marginal bone level changes.



Results

Fifty-seven implants (38 maxilla, 19 mandible) were placed in 46 patients (23 males, 23 females, aged between 18- 73 years). Ten implants were placed in post-extraction sockets. Four patients (four implants) withdrew from the study and were consequently classified as drop-outs. At the end of the study, only one implant was lost, in a healed site. All the surviving implants were stable, giving an overall 2-year survival rate of 97.6% (patient-based). One patient experienced pain and swelling after surgery: this was managed by giving anti-inflammatory and analgesic medication, and no further complications were reported. At the end of the study, the incidence of biologic complications was 1.8%. Prosthetic complications were more frequent, and amounted to 7.5%. In fact, three patients had their abutments loosened. All these abutments were re-inserted and screwed in again; however, these were considered as prosthetic complications. In addition, a ceramic fracture occurred in a metal-ceramic definitive crown, in the posterior maxilla of a male patient; this crown was removed and the clinician had to provide a new restoration for the patient. Finally, after 2-years of functional loading, the overall peri-implant marginal bone loss was 0.37 mm (± 0.22). In the healed site group, a 2-year marginal bone loss of 0.4 mm (± 0.22) was reported, while in post-extraction sockets the 2-year marginal bone loss amounted to 0.3 mm (± 0.22).

Conclusions

The immediate functional loading of single AnyRidge® implants seems to represent a safe and successful procedure. Further, long-term follow-up studies on a larger sample of patients are needed to confirm these results.

References

- 1 Luongo G, Lenzi C, Raes F, Eccellente T, Ortolani M, Mangano C.
Immediate functional loading of single implants: a 1-year interim report of a 5-year prospective multicenter study. Eur J Oral Implantol. 2014; 7(2): 187-199.
- 2 Benic GI, Mir-Mari J, Hämerle CH.
Loading protocols for single-implant crowns: a systematic review and meta-analysis. Int J Oral Maxillofac Implants. 2014; 29 Suppl: 222-238.
- 3 Farronato D, Mangano F, Briguglio F, Iorio-Siciliano V, Riccitiello F, Guarnieri R.
Influence of Laser-Lok surface on immediate functional loading of implants in single-tooth replacement: a 2-year prospective clinical study. Int J Periodontics Restorative Dent. 2014; 34(1): 79-89.

98,40%

PDL-Mediated Immediate Implant Placement using the “Root Membrane Technique”. 98,40% Success rate after 5 years of loading.**Siormpas K.⁽¹⁾, Kotsiotou-Siormpa E.⁽¹⁾, Gasparatos S.⁽²⁾, Trikka D.⁽²⁾, Kotsakis G.⁽³⁾, Mitsias ME.⁽²⁾**

1. Private Dental Clinic, Larissa, Greece, www.siormpasdclg.gr

2. Private practice, Athens, Greece, www.dental-center.eu

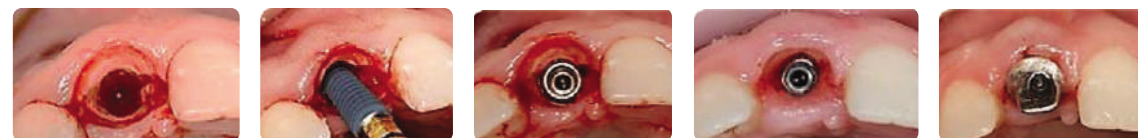3. Assistant Professor, University of Washington, Dental School, Department of Periodontology, USA

Introduction


Ridge preservation techniques limit but do not counter ridge resorption (Kotsakis et al, 2014). Immediate implant placement does not prevent ridge resorption. (Lee CT, et al. 2014). Loss of blood supply derived from the periodontal ligament (PDL) has been identified as a major etiologic factor for ridge resorption (Kotsakis et al. 2014). Root submergence has been utilized for over 40 years to ensure hard and consequently soft tissue dimensional stability (Salama et al, 2007). The “Root membrane” technique relies on the preservation of PDL, buccal plate and facial soft tissue esthetics via selective preservation of the buccal portion of the root (Mitsias et al, 2015). Recently, the first longitudinal data on implant success using this technique for immediate implant placement in maxillary anterior sites were presented (Siormpas K., et al, 2014).

Materials and Methods

Sixty-two fixtures (AnyRidge® MegaGen Co) with a length 10 to 13,0 mm, and a diameter of 3,5 to 5,0 mm were placed from 2010- 2011(5). Fifty eight patients (25 males and 33 females aged 23-66 years of age with an average of 47,3 years) participated in this private survey. All implants were immediately loaded with a cement-retained acrylic interim restoration. The final superstructure design of choice was cemented metal ceramic from the same lab- technician. The crown of the involved tooth was removed with a conventional chamber diamond bur under copious irrigation until the remaining tooth structure was leveled one millimeter above the osseous crest. The reason for not reducing it at the level, or even below the osseous crest was to maintain the dentogingival fibers intact to enhance soft tissue esthetics. The osteotomy sites were prepared by drilling through the long axis of the roots. This technique implements with gradual endo-root extraction (dentinotomy- osteotomy) of the palatal aspect of the root following the drilling sequence suggested by the implant manufacturer. The follow up period of patients observation was 5 years.

1. Female, 28 years old

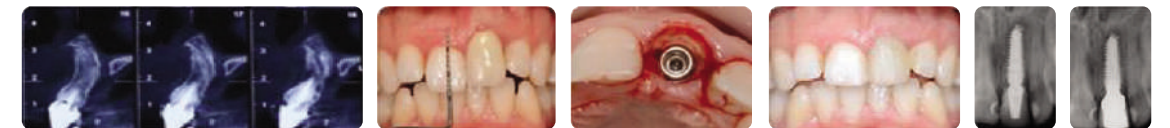
• Fig 1, Dentinotomy-osteotomy • Fig 2, The implant placement • Fig 3, The implant in post • Fig 4, Tissue configuration 4 months later • Fig 5, The final abutment in post



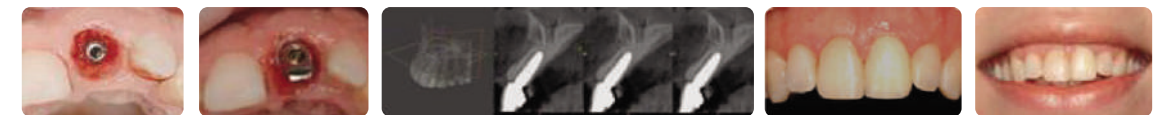• Fig 6, Initial CBCT (horizontal tooth fracture) • Fig 7, peri-apical X-ray • Fig 8, CBCT 4 years after implant post-loading • Fig 9, Esthetic result 5 years after implant post-loading.

Results

All sixty-two fixtures were successfully integrated except one that was lost, indicating a success rate of 98,4%. CBCT evaluation indicated that there was no bone loss during this period of time regarding the alveolar ridge.

2. Female, 32 years old

• Fig 1, Initial cat-scan (horizontal fracture of tooth) • Fig 2, Initial clinical view • Fig 3, Implant placement in contact with retained part of the root. • Fig 4, Provisional restoration • Fig 5,6, X-ray after implant placement and after the final restoration in post



• Fig 7, Peri-implant tissue configuration • Fig 8, Final abutment in place • Fig 9, Cat-scan 3 years after post loading • Fig 10, The final restoration in post • Fig 11, Final esthetic result

Conclusions

PDL-Mediated Ridge preservation (“Root membrane technique”) for immediate implants placement and loading in the aesthetic zone of the maxilla, has been proven to be a successful alternative method for the esthetics preservation of the tissues in this demanding area. More studies have to take place in order to establish this trend technique as a validated scientifically surgical procedure.

References

- 1 Kotsakis GA, Salama M, Chrepa V, Hinrichs J, Gaillard P. A randomized, blinded, controlled clinical study of particulate Anorganic Bovine Bone Mineral and Calcium Phosphosilicate Putty bone substitutes for alveolar ridge preservation. *Int J Oral Maxillofac Implants*. 2014 Jan-Feb;29(1):141-51
- 2 Lee CT, Chiu TS, Chuang SK, Tamow D, Stoupe J. Alterations of the bone dimension following immediate implant placement into extraction socket: systematic review and meta-analysis. *J Clin Periodontol*. 2014 Sep;41(9):914-26.
- 3 Salama et al, Root submergence has been utilized for over 40 years to ensure hard and consequently soft tissue dimensional stability. *Int J Periodontics Restorative Dent*. 2007 Dec;27(6):521-7.
- 4 Mitsias, M, Siormpas, K, Kotsiotou- Siormpa E, Prasad H, Garber, D, Kotsakis GA. A step-by-step description of immediate implant rehabilitation in the esthetic region utilizing the “Root-membrane” technique. *Int J Periodontics Rest. Dent*. February 2015;35(6):835-84
- 5 Siormpas, K, Mitsias, M, Kotsiotou- Siormpa E, Garber, D, Kotsakis GA. Immediate implant placement in the esthetic zone utilizing the “Root-membrane” technique: clinical results up to 5 years post-loading. *Int J Oral Maxillofac Implants*. 2014;29(6):1397-05.

12 months follow-up

SINUS LIFT CRESTAL APPROACH (MICA-KIT): EVALUATION OF CRESTAL HEIGHT VARIATION ONE YEAR POST-SURGERY

OSCAR ALONSO GONZALEZ (MD, DDS), SANTIAGO PASQUÍN C DE SOBREGRAU (MD, DMD), RAMON BUENECHEA IMAZ (MD,DMD,PHD), MERITXELL LOSADA MARTINEZ (DDS, MS)

Object

The aim of this study is to evaluate the variations of the crestal height after one-year crestal approach sinus lift technique (MICA).

Materials and Methods

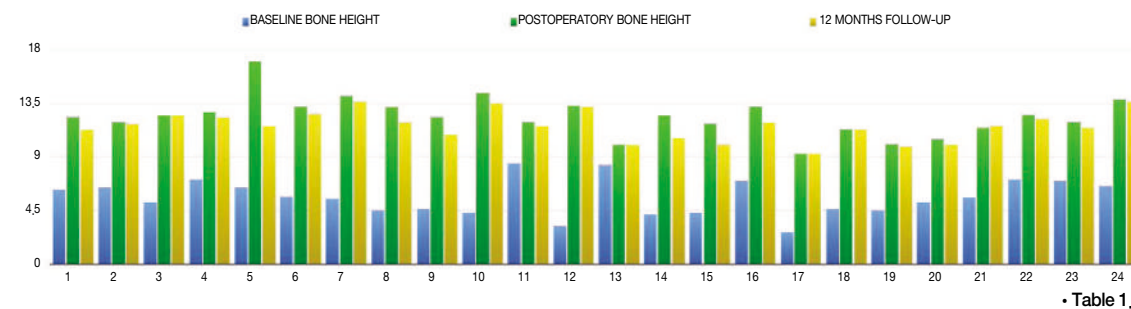
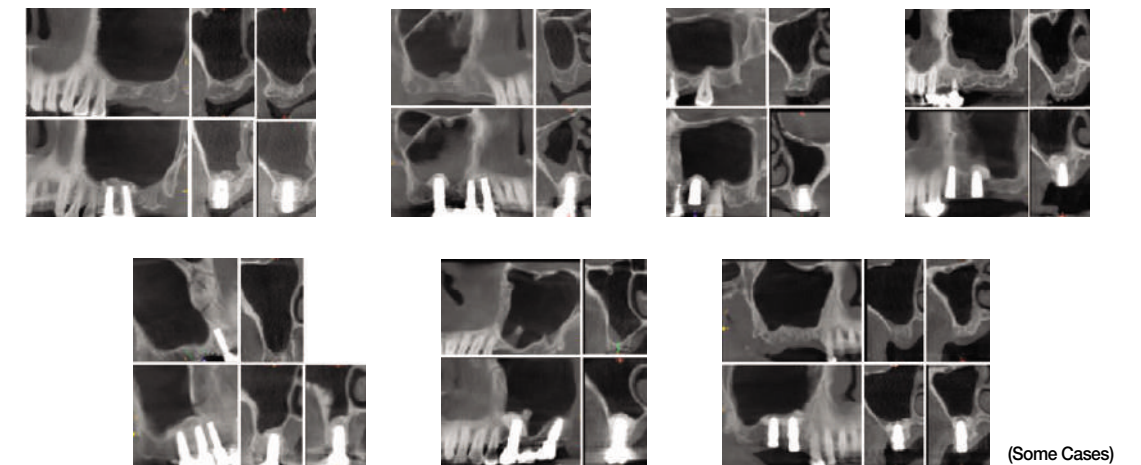
A total of 24 implants were placed in 18 patients (11 female and 7 male) through a MICA crestal Sinus lift technique (Megagen). Autogenous bone graft in combination with xenograft were used to regenerate the sinus in all cases. The baseline height of the of the ridge were recorded, Preoperatively by CBCT imaging. At the end of the surgery, another CBCT was performed to measure the final height achieved with MICA technique. After 12 months of follow-up a final CBCT was performed to corroborate the results.

Results

These results are presented in order to show the variation of the bone height with this technique end the implant survival after 12 months. The average width of the ridge was 10,3 mm (range of 6,8 to 14,2mm). The average baseline height was 5,6mm (range of 2,7 to 8,5mm). The postoperative average height was 12,4mm (range 9,3 to 17mm). The average height bone gain was 6,8mm (range 1,7 to 10,6mm). After 12 months the final crestal bone height was 11,7mm on average (range 9,3 to 13,7mm). Twenty-three implants were wide platform (22 implants of 5x10 mm and 1 implant of 5x8,5mm), and one implant regular platform (4x10mm). The only complication recorded was a membrane perforation without affecting implant survival.

Conclusions

The crestal sinus lift MICA technique demonstrated low intraoperative and postoperative complications. The immediate postoperative height obtained after the surgery compared to the measurement after 12 months shows a decrease in the total height. This reduction might be caused by the initial maturation and contraction of the blood clot and by the new bone formation.



References

- [1] Esposito M1, Gru- sovin MG, Rees J, Karasoulos D, Felice P, Alissa R, Worthington H, Coulthard P. Effectiveness of breast lift procedures for dental implant rehabilitation: a systematic review Cochrane, Eur J Oral Im- plantol, 2010 Spring.
- [2] G, Bräger U, Schmidlin K, Lang, Nkenke E1, Stelzle F. . The clinical results of elevation of the use of autogenous bone im- plants or bone substitutes 1/2eos: a systematic review. Clin Res Oral implants, 2009 Sep;20 Suppl 4:124 -33.
- [3] R. B. Summers, "an osteotome behind technical: part 3-less invasive to raise the floor of the womb", Digest, vol 15, no. 6, Pp. 698- 710, 199.. 7. Samuel Lee, DDS * , Grace Kang-Lee , DDS, Kwang-Bum Park, DDS, MS, PhD, Thomas have, DDS, MS "Window crestal sinus lift", minimally invasive, predictable and systematic approach for grafting.

2.3

2.3-fold increase in the proliferation of human gingival stem cells associated with culturing in the presence of BonePlus-MEGAGEN

Pablo Quiroz¹, Isabel Benjumeda², Sergio Tapia², Carola Millán^{2,3}, Juan Francisco Vivanco².

1, Hospital Dr. Gustavo Fricke, Viña del Mar, Chile.

2, Facultad de Ingeniería y Ciencias, Universidad Adolfo Ibáñez, Viña del Mar, Chile.

3, Facultad de Artes Liberales, Universidad Adolfo Ibáñez, Viña del Mar, Chile.

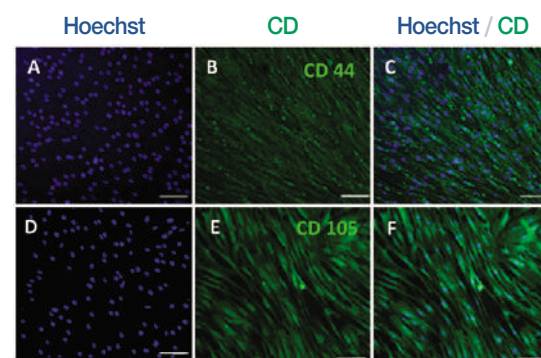
Objective

The aim of this study was to determine the integration and proliferation of human gingival mesenchymal stem cells (hGMSCs) in a Biphasic Tricalcium Phosphate (BTCP) scaffold in order to improve and shorten the osteogenic regeneration time of patients that will undergo dental implant fixation.

Materials & Methods

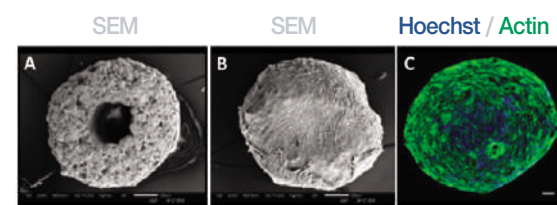
Stem cells used in the present study were obtained from gingival tissue from healthy patients and were amplified for posterior studies (up to 7 passages).

Stem cells were cultured in DMEM supplemented with FBS and maintained at 37 °C and 5% CO₂. Immunohistochemistry was used for cytoplasm and nuclear staining (Actin and Hoechst) and for mesenchymal cell characterization using the following markers: CD45, CD90 and CD105. BTCP, Bone Plus-MEGAGEN, were seeded with 250,000 - 500,000 cells and incubated at 37 °C for up to 5 weeks. Morphological analysis was performed by Scanning Electronic Microscopy (SEM) and Confocal Microscopy. Quantifications were performed using ImageJ, EZ-C1 FreeViewer, and statistical analysis was conducted by ANOVA with a significance level $p < 0.05$.

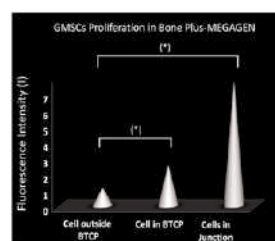


Human gingival mesenchymal stem cells (hGMSCs) characterization using mesenchymal markers.

Expression of mesenchymal stem cell markers in cells isolated from human gingival tissue. Cells were immunostained with mouse antibodies (Abs) specific for human CD44 (Fig. B,C) and CD105 (Fig. E,F) followed by incubation with Alexa 488 conjugated secondary Ab. Nuclei were stained using Hoechst (Fig. A,D). Images represent maximum projections from Z-Stack reconstructions obtained under a Confocal microscopy. Scale bar is 100µm.



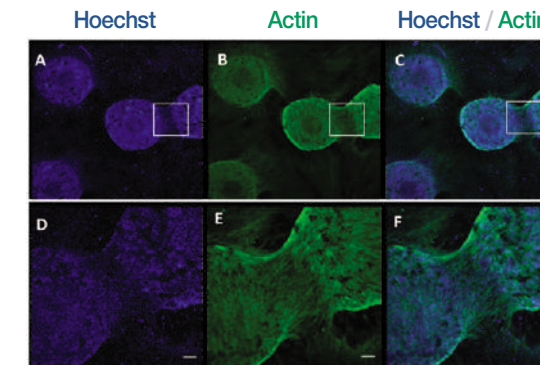
GMSC integration in a Tricalcium phosphate "Bone Plus-MEGAGEN".
A, SEM image of control condition showing a "Bone Plus-MEGAGEN" (BTCP) without cells.
B, SEM image of a BTCP seeded with hGMSCs and cultured for 2 weeks.
C, Immunofluorescence image showing cells stained with Hoechst and Actin (superposition of the two markers) and integrated in BTCP. Scale bar is 100µm.



Plot 1. Quantification of cell density in the presence of Bone Plus-MEGAGEN.

Fluorescence intensity signal (I) was quantified as an indicator of cell density (Hoechst positive cells). The results are representative of at least 3 independent experiments, $p < 0.05$.

The proliferation of GMSCs increased 2.3-fold in the presence of Tricalcium Phosphate Bone Plus-MEGAGEN.



Stem cell proliferation in the presence of Bone Plus-MEGAGEN.

Panels above represent the trend of hGMSCs seeded in Bone Plus-MEGAGEN to proliferate forming junctions, suggesting that BTCP contains bioactive molecules that promote cell migration and proliferation. After 5 weeks in culture, cells were immunostained with a specific marker for Actin (Fig. B, E). Nuclei were stained using Hoechst (Fig. A, D). Superposition of the previous two markers (Fig. C, F). Panels below (D, E, F) represent higher magnifications from the squared areas. Images were observed under a Confocal microscopy and fluorescence intensity signal was quantified as an indicator of cell density (see plot 1).

Conclusions

In order to provide a faster recovery rate and to avoid the difficulties associated to osteogenic regeneration treatments, the use of stem cells combined with Calcium Phosphate (CaP) based materials is becoming an interesting novel clinical therapy during the healing process of patients. CaP based materials contain bioactive molecules that promote cell migration and proliferation to the affected areas, but to date, the optimal combination between the CaP and the stem cell types remains unclear. We showed that a Calcium Phosphate Bioceramic (Bone Plus, MEGAGEN) in combination with gingival derived stem cells provides an optimal compatibility, as shown by our analysis of viability, integration and proliferation.

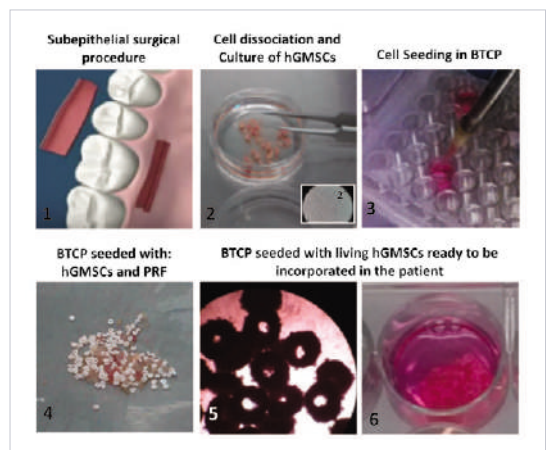
Additional studies are needed to incorporate new elements as growth factors in order to promote neovascularization. In this line, earlier experiments allowed us to observe that Platelet Rich Fibrin (PRF) has been an excellent complement for BTCP. These findings are relevant and promising and also suggest the need to perform further studies to understand the critical parameters relevant for clinical applications.

Results

Cell characterization using immunohistochemistry confirmed that cells derived from gingival tissues were mesenchymal stem cells in a high percentage ($\approx 90\%$), as described by previous research. Actin and Hoechst staining demonstrated the viability and compatibility between gingival derived stem cells and BTCP. SEM analysis showed that the scaffold was charged by cells, demonstrating a positive effect of BTCP on cell integration. Confocal Z Stack reconstruction analysis confirmed cell integration into BTCP and demonstrated a higher proliferation rate on Bone Plus MEGAGEN areas, compared to control condition. Results were observed to be statistically significant ($p < 0.05$).

Moreover, we found a trend showing a higher cell proliferation in areas between bioceramics (junctions), supporting the fact that BTCP contains bioactive molecules that promote cell migration and proliferation.

Process from Clinical (biopsy) to cell culture, BTCP/PRF seeding and back to Clinical for patient incorporation



References

- Annibali, S., et al, Craniofac Surg, 2013.
- Liu YK., et al, Biomed Mater 2009.
- Morsczeck, C., et al, First Edition, 2013.
- Wang F., et al, Stem Cells Dev, 2011.
- Zhang Q., et al, J Immunol, 2009.
- Zhang, Q., et al, Critical reviews in oral biology & medicine, 2012.
- Zhang, L., et al, Japanese dental science review, 2013.

2

2 years follow-up results in pre-shaped titanium mesh reconstruction of bone dehiscence around implants: a prospective study

IULIAN FILIPOV¹, CRISTIAN ROTARU², LUCIAN CHIRILA³

(1) MD, Minec, Bucharest, Romania

(2) MD, Minec, Bucharest, Romania

(3) Senior Lecturer "Carol Davila" University of Medicine and Pharmacy, Bucharest, Romania

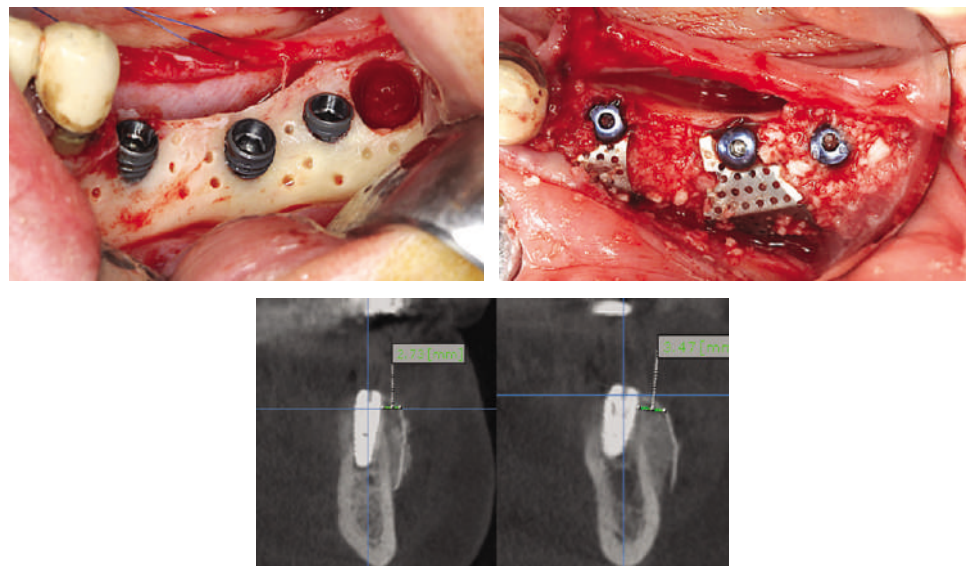
Object

The aim of the present review was to evaluate a specific bone regeneration method, focusing on the augmented obtained bone including implant survival, success and complication rate.

Materials and Methods

27 peri-implant bone defects were augmented with a mixture of autogenous bone grafts (harvested intraorally from the linia obliqua externa or from the drilling site) with allograft or xenograft, so as the deficiencies were completely filled, recreating the ideal amount of bone. Height of implant dehiscences (mean 4,8 mm) were measured in an apico-coronal direction using a periodontal probe. Horizontal augmentation was determined using computed tomography scans of the alveolar ridge postreconstruction. Augmented sites were covered with an individually micro titanium mesh which was rigidly affixed with a cover screw to the recipient site and a primary suture was performed.

At re-entry (mean interval 5,1 months) the titanium mesh were removed and bone regeneration assessed.



Results

A total of 24 patients, 11 males and 13 females, underwent maxillary or mandibular alveolar ridge regeneration by means of Ti-mesh and particulate autogenous bone graft in mixture (1:1) with allograft or xenograft bone. The post-operative healing was uneventful in 25 augmented dehiscences (92,59%). In 2 augmented sites (7,40%), early Ti-mesh exposure after 2 months' healing was managed with chlorhexidine mouthwash rinse for 5 weeks. Computed tomography scans of the alveolar ridge pre- and postreconstruction demonstrated mean horizontal augmentation of $2,8 \pm 0,47$ mm. Vertical component of the implant dehiscences were 100 % covered with newly regenerated bone (25 implants) and 70 % coverage with newly formed bone in cases with early exposure. At the re-entry procedure and removal of Ti-meshes, a dense connective tissue without any clinical signs of inflammation was present. All of the implants were retained after 2 years, yielding a 100% survival rate.

Conclusions

This 2-year prospective study demonstrated that implants placed into augmented bone using this technique exhibited peri-implant stability with high survival (100%) and success (92,59%) rates.

References

- [1] Clementini M, Morlupi A, Canullo L, Agrestini C, Barlattani A. Success rate of dental implants inserted in horizontal and vertical guided bone regenerated areas: a systematic review. Int J Oral Maxillofac Surg. 2012;41:847-52
- [2] Gongloff RK, Cole M, Whitlow W, Boyne PJ. Titanium mesh and particulate cancellous bone and marrow grafts to augment the maxillary alveolar ridge. Int J Oral Maxillofac Surg. 1986;15:263-8
- [3] Assenza B, Piattelli M, Scarano A, Lezzi G, Petrone G, Piattelli A. Localized ridge augmentation using titanium micromesh. J Oral Implantol. 2001;27:287-92

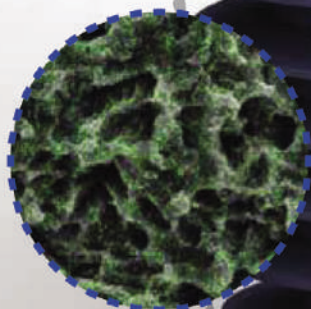
Why will AnyRidge work in any ridge?

Narrow upper diameter

To maximize preservation by minimizing stress on the cortical bone.

XPEED®

For faster, stronger osseointegration. New surface technology incorporating Ca^{2+} ions on the SLA treated surface. 100% elimination of any remaining acid from the conventional SLA process.



Tapered body

Excellent for simple installation and immediate loading.

Case1



Case2



Wider fixture in a narrow crest

To maximize long term survival of implants.

Knife-Threads

For smooth insertion and stronger primary stability. No cutting edge for minimum invasion. Ideal for soft bone cases.


Narrow apical diameter

For easier fixture insertion into a narrow ridge split incision

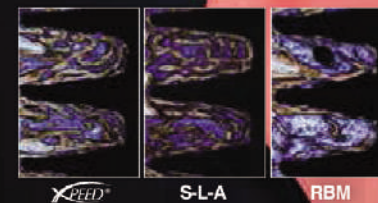
What is the fastest
Integration time ?

Ask AnyOne®

XPEED surface treatment
inducing rapid osseointegration




- Induction of faster and stronger Osseointegration by Ca^{2+} ion deposition on S-L-A surface
- Complete removal of acid residue by neutralization reaction during XPEED procedure.

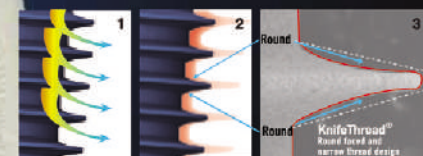


XPEED Surface Treatment presents much faster & stronger Osseointegration than RBM or S-L-A

High initial fixation!
Knife Thread



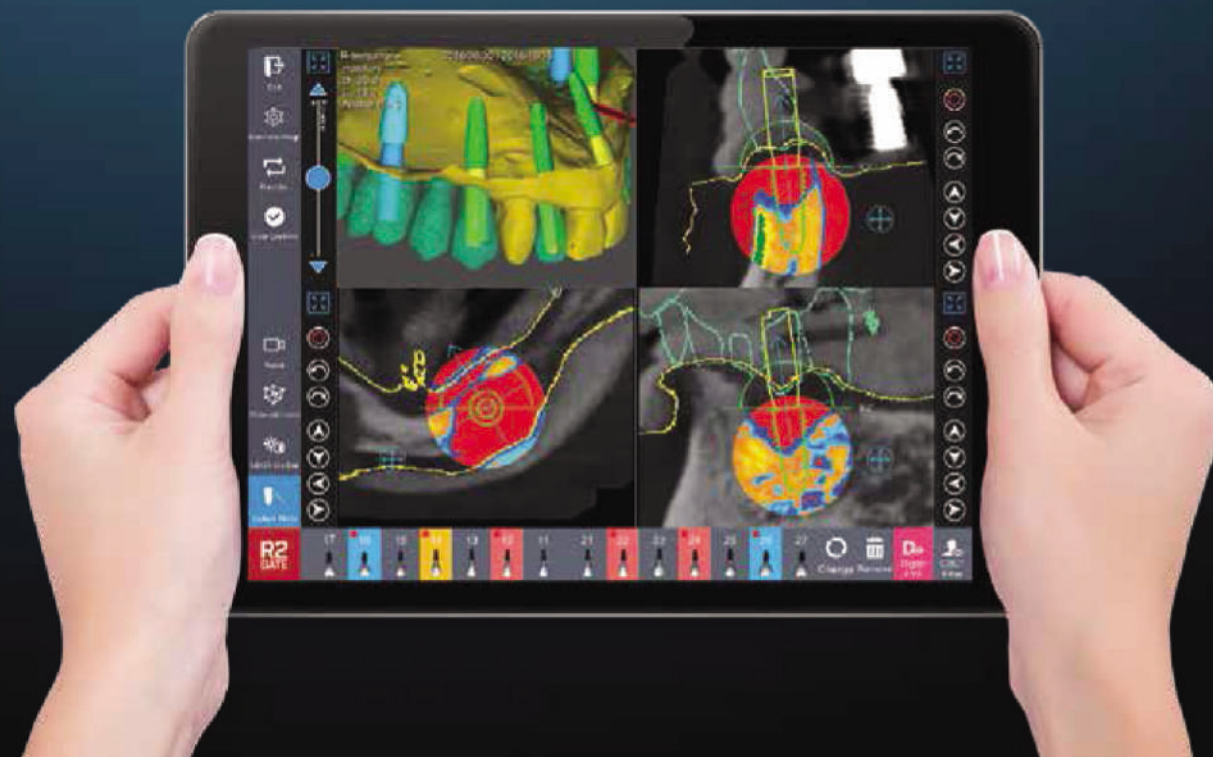
- Securement of initial stability with higher BIC
- Decentralize the stress on Cancellous bone
- Design that increases resistance and minimizes shearing force



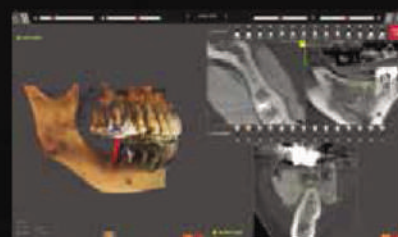1. Stable dispersion of stress with Buttress Thread shape
2. Easier Insertion with Sharp Thread shape
3. Increase the surface area of the round side compared with the straight side.

R2GATE™

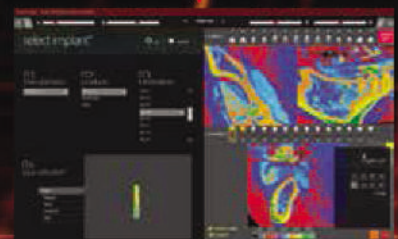
MegaGen 3D IMPLANT Planner
integrated with the state-of-art surgical guide system



USER PLAN

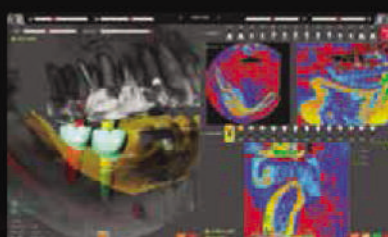


1. Open the CBCT(dicom) files.
2. Load the dummy implant

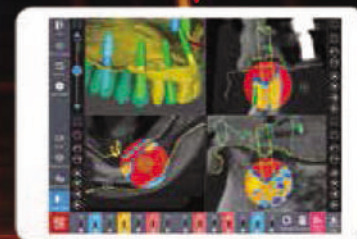

3. Check the bone shape and density.
4. Select implant and adjust the position & angulation.
5. Implant surgery or

R2GATE Precision diagnosis

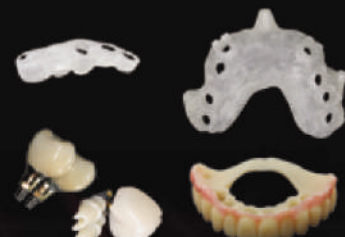

- STEP I** Add the model scan file and precision diagnostic wax-up.



- STEP II** Review and correct the implant position with R2GATE and confirm it.

R2GATE Guide & ONE-DAY Teeth



- STEP III** Receive the R2GATE Guide and prosthesis (or design files) together. If you have a CAD/CAM equipments, you can manufacture it by yourself.

Join MINEC today and become part of a growing network of experts in implant dentistry

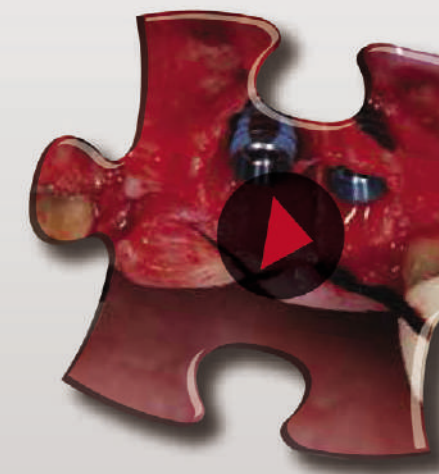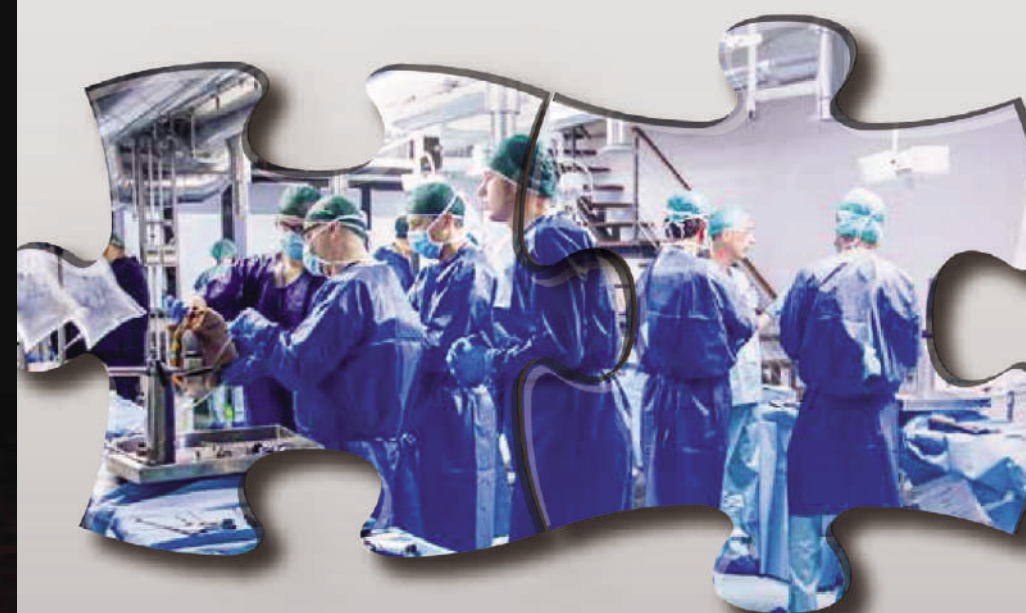


What is MINEC?

-The MINEC is a non-profit organization founded in 2002 following on the recommendations made by an international group of clinicians and researchers.

When you become a MINEC member,

- Share Clinical cases with experts and learn from each other to be a best implantologist
- Chance to get Lecture and Research support
- Receive advanced, scientific and academic information



To get more information, visit our website www.minec.ac

MegaGen Articles

Study & Evidence on **MegaGen Products**

Organized by



Head Office & Factory
Gangnam Office

45, Secheon-ro 7-gil, Dasa-eup, Dalseong-gun, Daegu, Korea
MegaGen Tower, 607 Seolleung-ro, Gangnam-gu, Seoul, Korea

Sponsored by



T. +82-1544-2285
T. +82-1566-2338